

03/21

memo – inOncology SPECIAL ISSUE

Congress Report ASCO 2021

A GLOBAL CONGRESS DIGEST ON SOLID TUMORS

Report from the ASCO Virtual Congress, 4th–8th June 2021

IMPRESSUM/PUBLISHER

Media owner and publisher: Springer-Verlag GmbH, Professional Media, Prinz-Eugen-Straße 8–10, 1040 Vienna, Austria, **Tel.:** +43(0)1/330 24 15-0, **Fax:** +43(0)1/330 24 26, **Internet:** www.springernature.com, www.SpringerMedizin.at. **Copyright:** © 2021 Springer-Verlag GmbH Austria. Springer Medizin is a Part of Springer Nature.
Managing Directors: Joachim Krieger, Juliane Ritt, Dr. Alois Sillaber. **Medical Writer:** Dr. Florence Boulmé. **Corporate Publishing:** Elise Haidenthaler.
Publishing Editor/Editorial Support: Anna Fenzl, PhD. **Layout:** Katharina Bruckner. **Published in:** Vienna. **Produced in:** Fulda. **Printer:** Druckerei Rindt GmbH & Co KG, Fulda, Germany.
The editors of "memo, magazine of european medical oncology" assume no responsibility for this supplement.

The Publisher does not assume any legal liability or responsibility for the accuracy, completeness, or usefulness of the information supplied herein, nor for any opinion expressed. The Publisher, its agent, and employees will not be liable for any loss or damage arising directly or indirectly from possession, publication, use of, or reliance on information obtained from this report. It is provided in good faith without express or implied warranty.

Reference to any specific commercial product or service does not imply endorsement or recommendation by the Publisher. All articles are peer-reviewed and protected from any commercial influence.

This issue is intended only for healthcare professionals outside the US, the UK and Australia.

Table of Contents

- 3 Preface
- 3 Novel approaches in gastric cancer
- 6 Checkpoint inhibition: predictors, resistance and immunogenomic features
- 9 PARP- and anti-PD-1-based strategies in breast and cervical cancer
- 13 Anti-PD-1 compounds targeting MSI-H/dMMR tumors
- 17 Early insights for CPI combinations in solid tumors
- 22 Esophageal cancer: taking immunotherapy one step further



© yalax / Getty Images / iStock

Editorial Board:

Hendrik-Tobias Arkenau, The Wellington Hospital, HCA Healthcare, London, UK

Christian Schauer, Krankenhaus der Barmherzigen Brüder, Graz, Austria

Gustavo Werutsky, MD, Latin American Cooperative Oncology Group (LACOG), Porto Alegre, Brazil

Lecture Board for this issue:

Todd M. Bauer, MD; Zineb Belcaid, MD; Ian Chau, MD; Hyun C. Chung, MD; Thorsten O. Götze, MD; Yelena Y. Janjigian MD; Christian Schauer, MD; Lin Shen, MD;



BeiGene

Supported by Boehringer Ingelheim and BeiGene in the form of an unrestricted grant

Preface

Dear Colleagues,

Because of the ongoing COVID-19 pandemic, this year's ASCO scientific meeting took place for the second time virtually from Friday, June 04, through Monday, June 08. During these five-day world's largest oncology conference, approximately 30,000 professionals attended online at least one of the 150 on-demand and broadcast sessions featuring over almost 5,000 abstracts, more than 2,000 poster presentations, 19 oral and 16 educational sessions, as well as opening and plenary sessions, award lectures, cancer-specific highlights sessions, and several clinical cancer symposia. This shows the urge interest of the global oncology community to get information about advances in cancer research, treatments, and patient care through both scientific and educational sessions.

Next to indication-specific oral sessions dedicated to solid and hematologic malignancies, multiple general cross-thematic sessions dealt with developmental therapeutics, either molecular targeted agents and tumor biology, or immunotherapy. A large part

of this publication is concerning new therapeutic options to overcome resistance to immune checkpoint inhibitors; especially, innovative strategies combining immunotherapy and targeted agents led to encouraging results in the treatment of patients with advanced or metastatic solid malignancies. The identification of predictive biomarkers to anticipate patients' susceptibility to immune-related adverse events was certainly also a main point of interest.

Novel combination approaches are currently being investigated in a wide range of solid tumors, including gastric cancers, breast cancer, cervical cancers, as well as esophageal cancers. Significant progress was communicated in breast cancer regarding PARP inhibitors, while a new potential synergetic treatment combination was reported in patients with advanced cervical cancer. More generally, new therapeutic strategies are now being explored in advanced solid tumors as combination between an anti-PD-1 antibody and different potential targets, including VEGF/Ang2, TIGIT, LAG3, PVRIG, TGF- β or HER2. Dual immunotherapy regimen or immunotherapy associated with chemotherapy are potential new standards of care in difficult-to-treat advanced or metastatic esophageal cancer. In addition, the clinical



© Dominiek Tyler

benefit of immune checkpoint inhibitors in MSI-H/dMMR solid tumors was confirmed and several innovative tissue-agnostic treatment options are currently under clinical investigation. Additionally, the effect of immunotherapy in terms of tumor elimination and pathologic response led to a better understanding of the dynamic changes in the immune microenvironment of the tumor.

Therefore, ASCO 2021 met once more its primary goal of sharing information between participants to ensure that all patients have access to the best knowledge in the field and benefit from latest therapeutic advances.

*Ian Chau, MD
Department of Medicine
The Royal Marsden Hospital
Sutton, Surrey, United Kingdom*

Novel approaches in gastric cancer

LEAP-005: lenvatinib plus pembrolizumab in gastric cancer

With more than 1 million newly diagnosed cases in 2020, gastric cancer was at the fifth place (5.6%) of the most frequent malignant diseases and accounted for nearly 8% of cancer deaths worldwide [1].

The multicohort, non-randomized, open-label, phase II LEAP-005 study (NCT03797326) was designed to evaluate the safety and efficacy of a combination – the anti-angiogenic multikinase inhibitor lenvatinib plus the anti-PD-1 antibody pembrolizumab – in patients with previ-

ously treated advanced solid tumors. Among the seven different cohorts, the results of the gastric cohort have been presented at the virtual scientific ASCO 2021 meeting [2]. The eligibility criteria were adults with confirmed metastatic and/or unresectable gastric cancer (GC), who received at least two prior lines of therapy, had measurable disease per RECIST v1.1, had a good performance status (ECOG PS 0-1) and provided a tissue sample evaluable for PD-L1 (programmed cell death-ligand 1) expression. For up to 35 cycles (approximately 2 years) or until confirmed disease progression, unacceptable toxicity, or withdrawal of consent, len-

vatib was administered daily (20 mg, orally), while patients received pembrolizumab (200 mg, IV) every three weeks; if patients experienced a clinical benefit, lenvatinib could be continued beyond two years. Objective response rate (ORR) according to RECIST v1.1 criteria assessed by a blinded independent central review (BICR) and safety were the co-primary endpoints. Secondary endpoints included disease control rate (DCR), duration of response (DOR), PFS (progression-free survival), and OS (overall survival).

Among the 31 eligible patients recruited, the mean age was 62 years

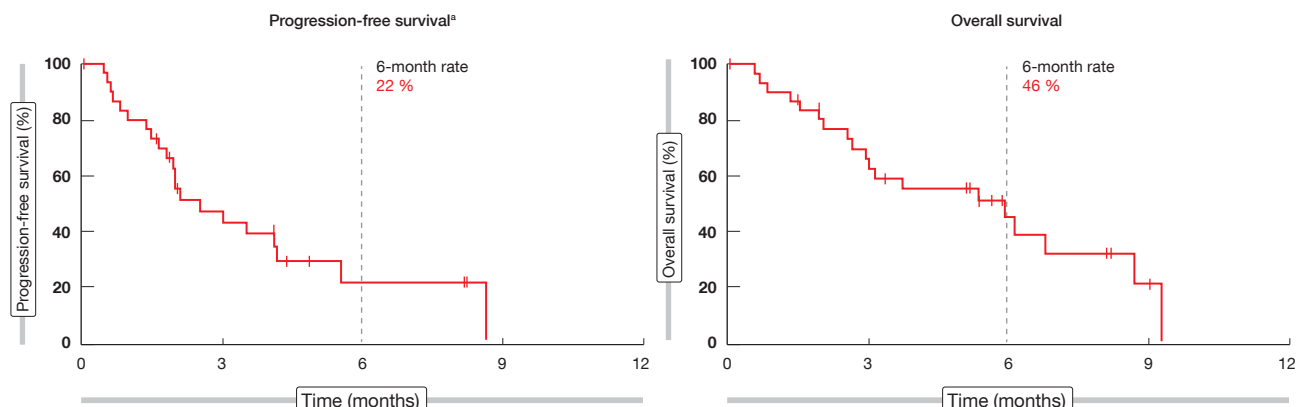


Figure 1: Median PFS and median OS in the LEAP-005 study in patients with gastric cancer

(range, 28-83), most of them (87 %) were male and 71 % had a combined PD-L1 positive score (CPS) ≥ 1 . At the time of the analysis (April 10, 2020), patients were for 7.0 months (range, 1.9-11.9) on treatment. An ORR of 10 % (95 % CI, 2-26) and a DCR of 48 % (95 % CI, 30-67) were achieved by the study population; in total, one patient (3 %) experienced a complete response (CR), while two patients (6 %) experienced a partial response (PR) and twelve patients (39 %) a stable disease. Median DOR was not reached yet. A median PFS of 2.5 months (range, 1.8-4.2; 6-month rate, 22 %) and a median OS of 5.9 months (range, 2.6-8.7; 6-month rate, 46 %) were attained (**Figure 1**). The most common treatment-related adverse events (TRAEs) observed in ≥ 20 % of patients were diarrhea (26 %) and fatigue (26 %). Immune-mediated AEs, which were experienced by seven patients (22 %), included hypothyroidism (n = 5) and hyperthyroidism (n = 2). In total, twelve patients (39 %) experienced grade 3 AEs, while no AE of grade 4 severity was seen; one patient died due to a gastrointestinal hemorrhage considered to be tumor-related by the investigator.

According to these data, the combination of lenvatinib plus pembrolizumab demonstrated promising antitumor activity and a manageable safety profile; therefore, the enrollment in the gastric cohort has been extended to 100 patients.

PARALLEL 303: pamiparib as maintenance monotherapy in GC

Some gastric cancer present platinum sensitivity, as well as genomic instability

(HRD, homologous recombination deficiency). Considering that cells with HRD are sensitive to poly (ADP-ribose) polymerase protein (PARP) inhibition [3], the use of PARP inhibitors as maintenance following platinum-based chemotherapy might be an efficient therapeutic strategy. The efficacy of PARP inhibitors in other cancer showing platinum sensitivity and higher levels of HRD has been already described, inclusive as maintenance therapy [4-6]. Pamiparib is an investigational PARP inhibitor showing sensitivity to HRD cells, which demonstrated its efficacy and tol-

erability in early-phase clinical study in advanced solid tumors [7, 8].

The double-blind, randomized, global, phase II PARALLEL 303 study (NCT03427814) compared the efficacy, safety, and tolerability of pamiparib against placebo as maintenance treatment in responders, who were defined as having a PR for ≥ 4 weeks or a CR after platinum-based first-line chemotherapy [9]. Eligible patients had histologically confirmed inoperable locally advanced or metastatic GC (adenocarcinoma of the stomach or gastroesophageal junction) and were enrolled in 128

TABLE 1
TEAEs reported in ≥ 10 % of patients in the PARALLEL 303 study

	Pamiparib (n = 71) N (%)	Placebo (n = 65) N (%)
Patients with at least one TEAE	65 (91.5)	61 (93.8)
Anemia	26 (36.6)	8 (12.3)
Nausea	23 (32.4)	11 (16.9)
Decreased appetite	19 (26.8)	8 (12.3)
Asthenia	15 (21.1)	11 (16.9)
Diarrhea	13 (18.3)	7 (10.8)
Abdominal pain	8 (11.3)	12 (18.5)
Abdominal pain upper	12 (16.9)	7 (10.8)
Vomiting	17 (23.9)	1 (1.5)
Constipation	8 (11.3)	7 (10.8)
Aspartate aminotransferase increased	9 (12.7)	5 (7.7)
Alanine aminotransferase increased	8 (11.3)	5 (7.7)
Peripheral sensory neuropathy	4 (5.6)	9 (13.8)
White blood cell count decreased	8 (11.3)	3 (4.6)
Dysphagia	3 (4.2)	8 (12.3)

TEAE, treatment-emergent adverse event. Data cut-off, June 16, 2020

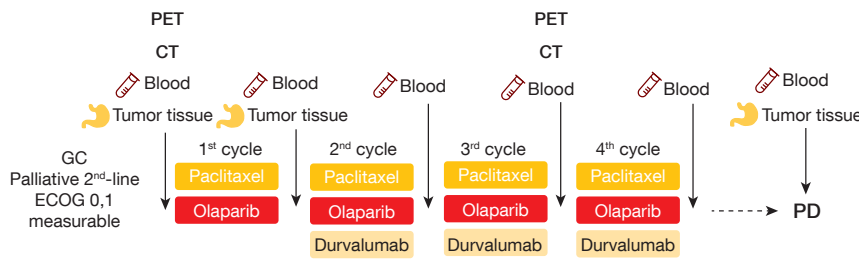


Figure 2: Study design of durvalumab combined to olaparib and paclitaxel

sites worldwide. The primary endpoint was PFS per RECIST v1.1, while time to subsequent treatment, ORR, DOR, time to response, OS and safety were the secondary endpoints. Data about PFS and safety were presented at ASCO 2021.

Overall, 136 patients were randomized 1:1 to receive either pamiparib (60 mg orally, twice daily) or placebo (twice daily) in 28-day cycles. At the time of analysis, 51.5 % of patients remained on study and 16.9 % remained on treatment. After a median follow-up of approximately 8.0 months in both arms, median PFS was longer with the investigational drug than with placebo, also not significantly different (3.7 vs 2.1 months; HR, 0.799; $p = 0.1428$). No significant clinical benefit was observed for median OS (10.2 with pamiparib vs 12.0 months with placebo) or ORR (7.7 vs 6.3, respectively) between both arms. Anemia (36.6 %) and nausea (32.4 %) among pamiparib-treated patients, as well as abdominal pain (18.5 %) in the control arm were the most frequently observed treatment-emergent adverse events (TEAEs). TEAEs led to treatment discontinuation in 11.3 % ($n = 8$) of patients in investigational arm and 3.1 % ($n = 2$) in placebo arm. Although pami-

parib did not meet its primary endpoint in this study, it showed a manageable safety profile consistent with that of other PARP inhibitors and no new safety signals were detected.

Biomarker relevance in second line therapy of GC

In the phase III GOLD study, the combination olaparib plus paclitaxel missed its primary endpoint – improvement of OS – compared to paclitaxel alone for the treatment of patients with gastric and gastroesophageal junction tumors, who progressed following the frontline therapy [10]. The PARP inhibitor olaparib not only induce DNA damage and cell death but is also involved in the up-regulation of PD-L1. Based on these findings, the authors hypothesize that the combination of a cytotoxic chemotherapy (paclitaxel) plus a PARP inhibitor (olaparib) plus an immune checkpoint inhibitor (durvalumab) might potentiate the antitumor activity in gastric cancer [11]. Therefore, a biomarker-oriented study was designed to explore the changes of tumor environment and to evaluate if the anti-PD-L1 addition might enhance the antitumor activity.

An ongoing phase II trial (NCT03579784) is enrolling patients with measurable lesions and histologically confirmed unresectable GC, who have failed to one prior chemotherapy. Patients previously exposed to anti-PD(L1)-1 or PARP inhibitors are excluded. Following the administration schema described on **Figure 2**, patients receive olaparib (150 mg twice daily on Day 1-28) plus paclitaxel (80 mg/m² intravenously, IV, on Day 1/8/15) for four cycles, with the addition of durvalumab (1.5g IV on Day 1) on cycles 2 to 4. At the time of progression, biopsy is mandatory; additionally, blood samples for biomarker analysis are collected at each treatment cycle. The DCR per RECIST v1.1 is the primary study endpoint, while the key secondary endpoints include ORR, PFS, OS, quality of life (QoL) and safety. This trial is intended to recruit 40 patients in Korea.

Adjuvant therapy in patients with resected GEA

Esophageal cancer is the sixth most common cause of cancer mortality globally; together, gastric and esophageal cancers were responsible for more than 1.3 million deaths in 2020 [1]. In patients with resectable gastroesophageal carcinoma (GEA), ESMO guidelines recommend a neoadjuvant chemotherapy as standard of care [12, 13], which might also be further administered after surgery; however, this regimen leads to suboptimal outcomes. In the CheckMate 577 study, adjuvant immunotherapy with nivolumab – an anti-PD-1 (programmed cell death protein 1) – has proven to be efficient in poor risk patients with GEA treated with neoadjuvant chemotherapy [14]. Moreover, nivolumab and ipilimumab – a CTLA-4 inhibitor – combined therapy showed antitumoral activity in advanced GEA. High risk patients with GEA are defined as those presenting metastatic lymph nodes or a microscopically incomplete surgical resection (R1). According to the data previously presented, high risk GEA patients treated with this dual adjuvant immunotherapy post-resection might have a better disease-free survival (DFS) than those who received standard post-operative chemotherapy [15].

In the international, open-label, randomized, phase II EORTC VESTIGE

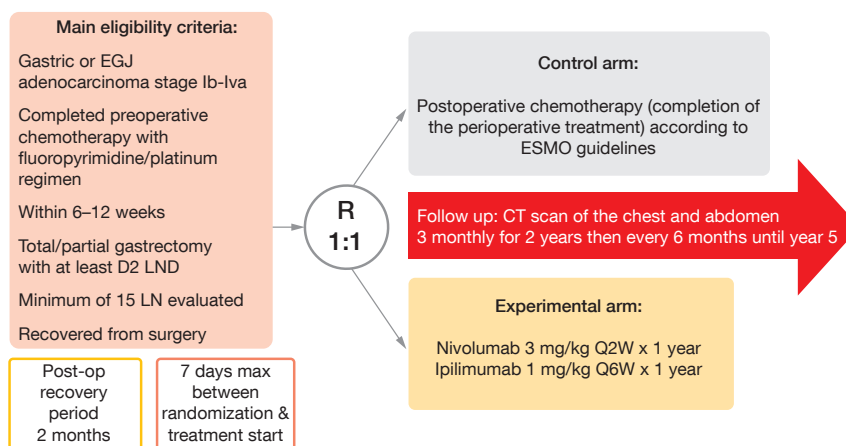


Figure 3: Design of the EORTC 1707 VESTIGE trial

study (NCT03443856), nivolumab plus ipilimumab versus chemotherapy are currently investigated as adjuvant therapy in high-risk GEA patients [16]. After a post-surgery recovery period of two months, eligible patients are rand-

omized 1:1 to receive for a year either nivolumab (3 mg/kg IV, biweekly) plus ipilimumab (1 mg/kg IV, every six weeks) or the same chemotherapy regimen as pre-operatively (**Figure 3**). DFS will be primarily analyzed, and OS,

safety, toxicity, and QoL secondarily evaluated. As the recruitment opened in August 2019, 95 out of 240 planned patients have been already enrolled until May 2021 in 22 sites in Europe and Israel. ■

REFERENCES

- Sung H et al.**, Global Cancer Statistics 2020: GLOBOCAN Estimates of Incidence and Mortality Worldwide for 36 Cancers in 185 Countries. *CA Cancer J Clin* 2021; 71(3): 209-249.
- Cheol Chung Y et al.**, LEAP-005: A phase 2 multicohort study of lenvatinib plus pembrolizumab in patients with previously treated selected solid tumors—Results from the gastric cancer cohort. *J Clin Oncol* 2021; 39(suppl 15): abstr 4030.
- van Wilpe S et al.**, Homologous Recombination Repair Deficiency and Implications for Tumor Immunogenicity. *Cancers (Basel)* 2021; 13(9).
- Swisher EM et al.**, Rucaparib in relapsed, platinum-sensitive high-grade ovarian carcinoma (ARIEL2 Part 1): an international, multicentre, open-label, phase 2 trial. *Lancet Oncol* 2017; 18(1): 75-87.
- Mirza MR et al.**, Niraparib Maintenance Therapy in Platinum-Sensitive, Recurrent Ovarian Cancer. *N Engl J Med* 2016; 375(22): 2154-2164.
- Coleman RL et al.**, Rucaparib maintenance treatment for recurrent ovarian carcinoma after response to platinum therapy (ARIEL3): a randomised, double-blind, placebo-controlled, phase 3 trial. *Lancet* 2017; 390(10106): 1949-1961.
- Xiong Y et al.**, Pamiparib is a potent and selective PARP inhibitor with unique potential for the treatment of brain tumor. *Neoplasia* 2020; 22(9): 431-440.
- Xu B et al.**, Pamiparib dose escalation in Chinese patients with non-mucinous high-grade ovarian cancer or advanced triple-negative breast cancer. *Cancer Med* 2021; 10(1): 109-118.
- Ciardello F et al.**, PARALLEL 303: Phase 2 randomized study of pamiparib vs placebo as maintenance therapy in patients (pts) with inoperable locally advanced or metastatic gastric cancer that responded to platinum-based first-line (1L) chemotherapy. *J Clin Oncol* 2021; 39(suppl 15): abstr 3109.
- Bang YJ et al.**, Olaparib in combination with paclitaxel in patients with advanced gastric cancer who have progressed following first-line therapy (GOLD): a double-blind, randomised, placebo-controlled, phase 3 trial. *Lancet Oncol* 2017; 18(12): 1637-1651.
- Kim T et al.**, Biomarker-oriented study of durvalumab in combination with olaparib and paclitaxel in gastric cancer: A phase 2 trial-in-progress. *J Clin Oncol* 39 2021; 39(suppl 15): abstr TPS4153.
- Lordick F et al.**, Oesophageal cancer: ESMO Clinical Practice Guidelines for diagnosis, treatment and follow-up. *Ann Oncol* 2016; 27(suppl 5): v50-v57.
- Smyth EC et al.**, Gastric cancer: ESMO Clinical Practice Guidelines for diagnosis, treatment and follow-up. *Ann Oncol* 2016; 27(suppl 5): v38-v49.
- Kelly R et al.**, Adjuvant nivolumab in resected esophageal or gastroesophageal junction cancer (EC/GEJC) following neoadjuvant chemoradiation therapy (CRT): first results of the CheckMate 577 study. *Ann Oncol* 2020; 31(suppl 4): S1142-S1215.
- Smyth EC et al.**, Checkpoint inhibitors for gastroesophageal cancers: dissecting heterogeneity to better understand their role in first-line and adjuvant therapy. *Ann Oncol* 2021; 32(5): 590-599.
- Smyth E et al.**, EORTC 1707 VESTIGE: Adjuvant immunotherapy in patients with resected gastric cancer following preoperative chemotherapy with high risk for recurrence (ypN+ and/or R1)—An open-label randomized controlled phase II study. *J Clin Oncol* 2021; 39(suppl 15): abstr TPS4156.

Checkpoint inhibition: predictors, resistance and immunogenomic features

Predictors of immunotoxicity to checkpoint inhibitors

Immune checkpoints, such as cytotoxic T-lymphocyte associated protein-4 (CTLA-4) or programmed cell death protein 1 (PD-1), downregulate T-cell responses and are crucial for self-tolerance, which protects the body against attacking cells indiscriminately [1]. Tumor cells hijack this mechanism to evade the immune system through the activation of immune checkpoints and inhibition of the T-cell response [1]. Immune checkpoint inhibitors (CPIs) block these pathways, thus enhancing the anticancer immunity [1, 2]. CPIs have changed the treatment landscape across various tumor entities due to durable clinical response [3]. However, specific immune-related adverse events

(irAEs) have been described in various clinical trials [2, 4]. There is an unmet need to identify predictive biomarkers to anticipate patients' susceptibility to irAEs [5]. So far, data specifically linking the tumor immune response to the risk of experiencing irAEs are scarce [6].

The analyzed population included 472 patients with various cancer entities who had tumor immune profiling performed on paraffin embedded formalin fixed archival tumor samples using the omniseq immune report card [6]. The patients subsequently underwent CPI therapy. The immune report card enclosed the enumeration of tumor infiltrating lymphocytes (TILs) by immunohistochemistry (IHC) and TIL-associated genes by RNA-sequencing, programmed cell death 1 ligand 1 (PD-L1) expression via IHC, and tumor mutational burden

(TMB) via DNA-sequencing. The irAEs (type and grade) were investigated based on retrospective patient chart review, and their association with immune biomarkers analyzed statistically.

More than half of the patients had lung cancer (55%), 9% ovarian cancer, and 6% melanoma. The median age of the patients was 61 (range, 53-70) and 56% were women. Most of the patients received an anti-PD-1/PD-L1 treatment (94%), while 6% had a combination therapy. Among the 37% of patients who developed irAEs, 3% had grade ≥ 3 irAEs. The most affected organs were the skin (11%), thyroid gland (10%), and gastrointestinal tract (9%).

An increased number of TILs was associated with a high risk for any irAEs ($p = 0.04$; OR, 1.74, 95% CI: 1.03-2.93), but only in males ($p = 0.006$; OR, 3.60;

Subgroup	≤ 30 # patients with irAE/total # patients (%)	≥ 70 # patients with irAE/total # patients (%)	Odds Ratio (95 % CI)	P-value
Overall	113/330 (34.2 %)	35/73 (47.9 %)	1.77 (1.05 to 2.96)	0.03
Monotherapy	96/306 (31.4 %)	35/73 (47.9 %)	2.02 (1.18 to 3.42)	0.009
Lung Cancer	54/154 (35.1 %)	31/59 (52.5 %)	2.05 (1.10 to 3.70)	0.03
Sex				
Male	56/142 (39.4 %)	12/37 (32.4 %)	0.7371 (0.3398 to 1.62)	0.57
Female	57/188 (30.3 %)	23/36 (63.9 %)	4.066 (1.893 to 8.320)	0.0002
Age				
< 65	58/197 (29.4 %)	19/40 (47.5 %)	2.168 (1.065 to 4.334)	0.04
≥ 65	55/133 (41.3 %)	16/33 (48.5 %)	1.335 (0.6059 to 2.901)	0.03

Figure 1: Association between PD-L1 expression and risk for irAEs

95 % CI, 1.38-8.96). Patients who had PD-1/PD-L1 monotherapy and/or lung cancer showed a strong association ($p = 0.02$; OR, 1.99; 95 % CI: 1.12-3.41 and $p = 0.01$; OR, 2.36; 95 % CI: 1.21-4.61, respectively). A significant relation between a high PD-L1 expression - defined as >70 % via IHC - and an increased risk for any irAEs ($p = 0.03$; OR, 1.77, 95 % CI: 1.05-2.96) was also observed (Figure 1). Women ($p = 0.0002$; OR, 4.07; 95 % CI: 1.89-8.32) and patients <65 years

($p = 0.04$; OR, 2.17; 95 % CI: 1.07-4.33) revealed to have a high risk to develop irAEs. A high TMB expression was not associated with a more elevated risk for irAEs, except in the female population ($p = 0.01$) or in breast cancer patients ($p = 0.03$). The study demonstrated a correlation between the tumor immune environment and the immune toxicity, as increased TILs and a high PD-L1 expression were associated with an elevated

risk for irAEs in patients receiving immunotherapy.

NBTXR3: Overcoming resistance to anti-PD-1 therapy

The success of CPIs has been largely driven by unprecedented durability of responses, which can last for years even in absence of continuous treatment [7]. However, resistance to CPIs, which has been described in more than 80 % of treated patients, is challenging [8]. Radiotherapy (RT) combined to immunotherapy has been previously shown to improve CPI response rates [9, 10].

NBTXR3 is a novel radioenhancer which is administered via a single intratumoral injection and activated by RT. NBTXR3 was designed to enhance the ionizing energy deposit inside tumor cells - without increasing the toxicity in the surrounding healthy tissue - to trigger tumor cell death and to prime an adaptive immune response. In preclinical settings, this radioenhancer showed antitumor efficacy in various tumors; especially in the combination NBTXR3 plus radiation therapy, a local and a systemic control, as well as an induction of the immune response, were observed in mice [11-13]. Moreover, in in vivo tumor models, activated NBTXR3 increased the local efficacy of PD-1 therapy compared to RT alone and improved distant tumor control via an abscopal effect [14]. In April 2019, NBTXR3 received CE Mark in Europe for the treatment of locally advanced soft tissue sarcoma, and FDA fast track designation in 2020 for patients with locally advanced head and neck squamous cell carcinoma (HNSCC) who are not eligible for a platinum-based chemotherapy [15-17]. New data recently presented at ASCO 2021 showed that NBTXR3 activated through radiation acts synergistically with anti-PD-1 therapy to enhance the therapeutic index of the RT and to overcome PD-1 resistance [14, 18].

An ongoing multicenter, open-label, non-randomized, phase I, first-in-human study evaluates the safety and tolerability of RT-activated NBTXR3 in combination with anti-PD-1 in three cohorts. The first cohort includes patients with locoregional recurrent (LRR) or recurrent and metastatic (R/M) HNSCC at the target lesion in a previously irradi-

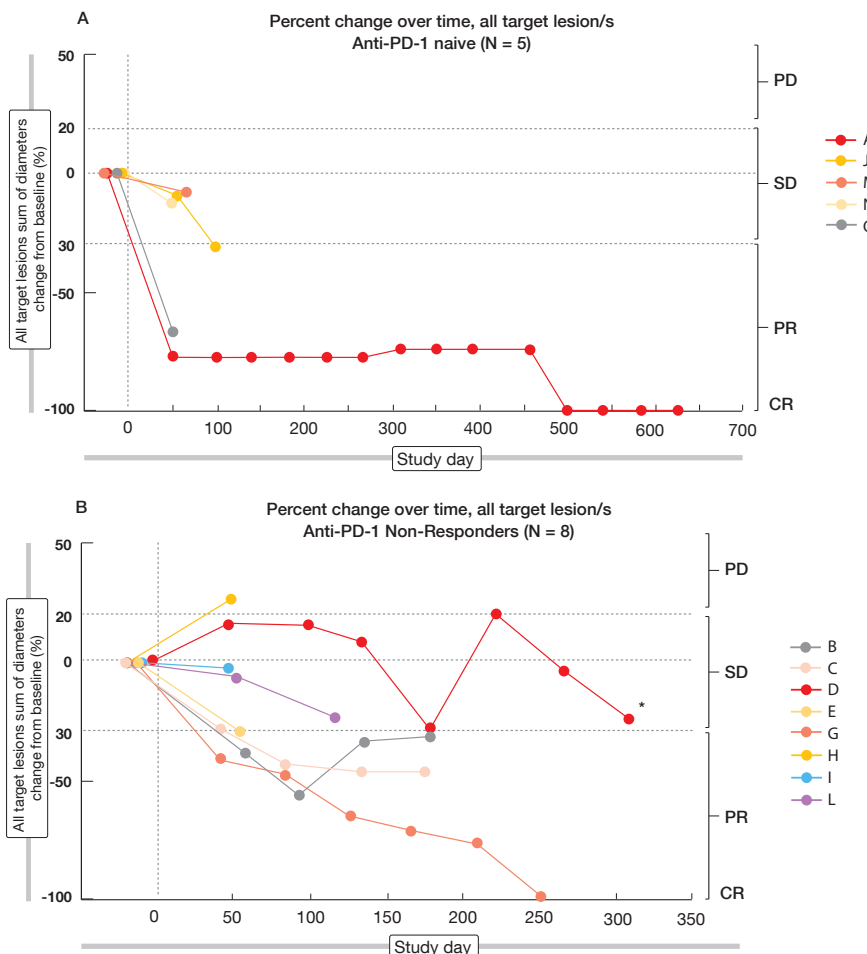


Figure 2 A, B: Change over time related to baseline in tumor size stratified by anti-PD-1 status
* Patient D: partial complete response based on biopsy sample located in the target lesion

ated field. In cohort 2 and 3, patients with respectively lung or liver metastases from any primary cancer eligible for anti-PD-1 treatment are enrolled [14, 18]. About 60 patients will receive RT-activated NBTXR3 in combination with an approved anti-PD-1 therapy (NCT03589339). Primary endpoints enclose the determination of the recommended phase 2 dose, dose limiting toxicities and maximum tolerated dose. Secondary objectives include antitumor response (objective response rate by RECIST 1.1), safety, and feasibility of the NBTXR3 injection. First results demonstrated tumor regression in 10 out of 13 patients evaluable for tumor responses, regardless of prior anti-PD-1 exposure [14]. Four out of five anti-PD-1 naïve patients experienced a regression; ORR reached 60 %, including one complete response (CR) (**Figure 2A**). In anti-PD-1 non-responders, 78 % (n = 6) had post-treatment tumor regression and ORR was 50 % (1 CR and 2 partial responses) (**Figure 2B**). Altogether, among 16 serious adverse events (SAE) observed, four were related to NBTXR3 or injection related, and included hyperglycemia, pneumonitis, and soft tissue necrosis.

Taken together, this data underline the immune modulation effect of radiotherapy-activated NBTXR3, not only as single agent, but also in combination with an anti-PD-1 treatment.

Neoadjuvant immunotherapy effect on tumor microenvironment

In patients with resectable esophageal or gastroesophageal junction (E/GEJ)

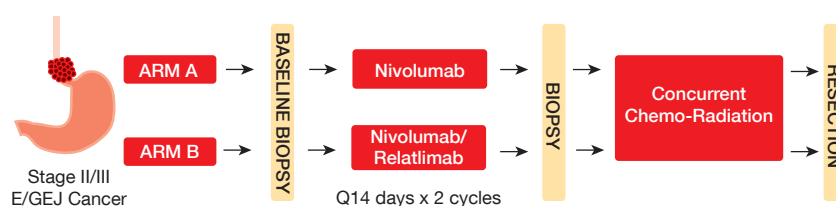


Figure 3: Study design, including sample collection timeline

cancer, the standard-of-care neoadjuvant chemoradiation is associated with a high recurrence rate [20]. In the CheckMate 577 trial, the treatment with the CPI nivolumab as adjuvant therapy following neoadjuvant chemoradiation and surgery significantly increased disease-free survival in patients with stage II/III esophagogastric cancer [21]. In a study reported at ASCO 2021, multi-omics analyses were performed to determine the immune and genomic landscape contributing to pathologic response in patients with E/GEJ cancer treated with an immune checkpoint blockade therapy [22, 23]. This phase IB study assessed the safety of two cycles anti-PD-1 nivolumab alone or nivolumab plus the anti-LAG3 relatlimab with chemoradiation in the preoperative setting (NCT03044613). Serial tumor samples from 23 patients were collected prior to therapy, after two cycles of CPI induction, and at resection (**Figure 3**). Pathologic response was measured by tumor regression at resection. Median follow up was 23 months post-surgery. Overall, 48 serial tumor samples were analyzed via bulk RNA sequencing (RNAseq), while 22 baseline tumor and normal DNA pairs were ana-

lyzed by whole exome sequencing (WES) to find somatic mutations and generate tumor mutation burden (TMB) estimates.

After immunotherapy induction, a significant upregulation of interferon-alpha (IFN- α), interferon-gamma (IFN- γ), tumor-necrosis factor- α (TNF- α) and antigen presentation related genes were detected compared to baseline ($p < 0.0001$). On the other hand, E2F targets ($p = 0.002$), G2M checkpoint genes ($p = 0.005$) and DNA damage repair genes ($p = 0.004$) were significantly downregulated following CPI neoadjuvant treatment. Patients who reached a pathologic complete response (pCR) were those whose tumors harbored a high number of expressed mutations ($p = 0.026$). A significantly higher density of intratumoral activated M1 macrophages was observed post-induction with CPI in patients with pCR ($p = 0.0034$). Additionally, TMB was not a predictive marker of a pathologic response ($p = 0.22$).

In summary, CPI neoadjuvant therapy induced an inflammatory immune response in the tumor microenvironment which was associated with tumor elimination and pathologic response. ■

REFERENCES

- Li B et al., Immune Checkpoint Inhibitors: Basics and Challenges. *Curr Med Chem* 2019; 26(17): 3009-3025.
- Baxi S et al., Immune-related adverse events for anti-PD-1 and anti-PD-L1 drugs: systematic review and meta-analysis. *Bmj* 2018; 360: k793.
- Tray N et al., Predictive Biomarkers for Checkpoint Immunotherapy: Current Status and Challenges for Clinical Application. *Cancer Immunol Res* 2018; 6(10): 1122-1128.
- Ramos-Casals M et al., Immune-related adverse events of checkpoint inhibitors. *Nat Rev Dis Primers* 2020; 6(1): 38.
- Gibney GT et al., Predictive biomarkers for checkpoint inhibitor-based immunotherapy. *Lancet Oncol* 2016; 17(12): e542-e551.
- Alexander W et al., Using the tumor microenvironment to identify predictors of immunotoxicity to checkpoint inhibitors. *J Clin Oncol* 2021; 39(suppl 15; abstr 2545).
- Schoenfeld AJ et al., Acquired Resistance to Immune Checkpoint Inhibitors. *Cancer Cell* 2020; 37(4): 443-455.
- Sharma P et al., Immune checkpoint targeting in cancer therapy: toward combination strategies with curative potential. *Cell* 2015; 161(2): 205-14.
- Hwang WL et al., Safety of combining radiotherapy with immune-checkpoint inhibition. *Nat Rev Clin Oncol* 2018; 15(8): 477-494.
- Postow MA et al., Immunologic correlates of the abscopal effect in a patient with melanoma. *N Engl J Med* 2012; 366(10): 925-31.
- Maggiorella L et al., Nanoscale radiotherapy with hafnium oxide nanoparticles. *Future Oncol* 2012; 8(9): 1167-81.
- Marill J et al., Hafnium oxide nanoparticles: toward an in vitro predictive biological effect? *Radiat Oncol* 2014; 9: 150.
- Zhang P et al., Radiotherapy-Activated Hafnium Oxide Nanoparticles Produce Abscopal Effect in a Mouse Colorectal Cancer Model. *Int J Nanomedicine* 2020; 15: 3843-3850.
- Seiwert TY et al., Overcoming resistance to anti-PD-1 with tumor agnostic NBTXR3: From bench to bed side. *J Clin Oncol* 2021; 39(suppl 15; abstr 2591).
- Anselmo AC et al., Nanoparticles in the clinic: An update. *Bioeng Transl Med* 2019; 4(3): e10143.
- Bonvalot S et al., NBTXR3, a first-in-class radioenhancer hafnium oxide nanoparticle, plus radiotherapy versus radiotherapy alone in patients with locally advanced soft-tissue sarcoma (Act. In.Sarc): a multicentre, phase 2-3, randomised, controlled trial. *Lancet Oncol* 2019; 20(8): 1148-1159.
- Hoffmann C et al., Phase I dose-escalation study of NBTXR3 activated by intensity-modulated radiation therapy in elderly patients with locally advanced squamous cell carcinoma of the

oral cavity or oropharynx. *Eur J Cancer* 2021; 146: 135-144.

18 Shen C et al., A phase I trial evaluating NBTXR3 activated by radiotherapy in combination with nivolumab or pembrolizumab in patients with advanced cancers. *J Clin Oncol* 2021; 39(suppl; abstr 2590).

19 Baere TD Phase I/II Study Of Radiation Enhancing Hafnium Oxide Nanoparticles NBTXR3 Activated by SBRT in HCC and Liver Metastases

Patients. *international journal of radiation oncology, biology, physics* 2020; 108(3).

20 Blum Murphy M et al., Pathological complete response in patients with esophageal cancer after the trimodality approach: The association with baseline variables and survival-The University of Texas MD Anderson Cancer Center experience. *Cancer* 2017; 123(21): 4106-4113.

21 Kelly RJ et al., Adjuvant Nivolumab in Resected Esophageal or Gastroesophageal Junc-

tion Cancer. *N Engl J Med* 2021; 384(13): 1191-1203.

22 Anagnostou V et al., Multimodal genomic features predict outcome of immune checkpoint blockade in non-small-cell lung cancer. *Nat Cancer* 2020; 1(1): 99-111.

23 Belcaid Z et al., Immunogenomic features of pathologic response to neoadjuvant immune checkpoint blockade in esophageal cancer. *J Clin Oncol* 2021; 39(suppl 15; abstr 4042).

PARP- and anti-PD-1-based strategies in breast and cervical cancer

Talazoparib in germline BRCA1/2-mutated breast cancer ...

Breast cancer (BC) is the most diagnosed cancer in women and the leading cause of cancer death in females [1]. It has been recently shown that approximately 38 % of female patients younger than 40 years presenting with triple-negative breast carcinomas (TNBC) harbored a germline mutation in breast cancer (BC) susceptibility genes 1 or 2 (gBRCA1/2m) [2]. Treatment options are limited for patients with gBRCA1/2m BC, and the presence of these genetic alterations is associated with younger age at diagnosis, aggressive disease, dismal prognosis and higher risk of recurrence [3]. The enzyme poly (adenosine diphosphate-ribose) polymerase (PARP) plays an important role in the regulation of single-strand DNA breaks and PARP inhibitors induce tumor cell death due to accumulation of irreparable DNA damages [4]. Moreover, PARP inhibitors are well tolerated, oral targeted therapies [3]. Therefore, PARP inhibitors such as talazoparib are a welcome addition to the treatment arsenal for patients with gBRCA1/2m human epidermal growth factor receptor 2-negative (HER2-) locally advanced or metastatic BC [5]. Based on the findings of the pivotal phase III EMBRACA trial (NCT01945775), talazoparib received approval in October 2018 in the USA and in June 2019 in Europe for the treatment of adult patients with gBRCA1/2m, HER2-negative locally advanced or metastatic BC [5-7]. In this trial, talazoparib met its primary endpoint by show-

ing a significantly better median progression-free survival (PFS) versus physician's choice of chemotherapy (PCT) in this population (8.6 vs 5.6 months; HR, 0.54; 95 % CI, 0.41-0.71; $p < 0.001$) [5]. A previous analysis of the EMBRACA trial investigating biomarkers associated with LONG and SHORT responders revealed that a tumor *MYC* amplification was associated with shorter overall survival (OS) in TNBC patients treated with talazoparib [8].

At ASCO virtual scientific meeting 2021, Ettl et al. reported about a retrospective post hoc analysis describing the clinical characteristics of LONG and SHORT responders following treatment with talazoparib or PCT in the EMBRACA study [9]. Patients in the intent-to-treat (ITT) population were mapped into two groups based on their response: LONG responders included patients with an OS ≥ 30 months and a duration of response (DOR) ≥ 24 months in the talazoparib arm ($n=37$) and an OS ≥ 30 months in the PCT arm ($n=34$); SHORT responders included patients in either arm with a PFS event ≤ 12 weeks (talazoparib arm, $n=40$; PCT arm, $n=32$). At the data cutoff date of September 30, 2019, a higher proportion of LONG responders with hormone receptor-positive (HR+) BC and no prior chemotherapy (CT) for locally advanced or metastatic BC was observed; additionally, a greater proportion of SHORT responders had TNBC and received ≥ 2 prior CT regimens for locally advanced or metastatic BC or platinum therapy. Approximately half of the LONG responders receiving talazoparib (51.4 %) and 91.2 % of the LONG responders

treated with PCT had subsequent anti-neoplastic treatment. Moreover, at data cut off, more LONG responders (43.2 %) under talazoparib were still on treatment compared to the PCT arm (2.9 %). The median treatment duration for LONG responders was 33.5 months in the experimental arm and 7.6 months in the control arm, whereas patients from the SHORT group responded only 2.0 months in the talazoparib arm and 1.4 months in the PCT arm. As these findings were based on a limited data set, further investigations with a larger number of patients in this setting might be warranted.

... and in somatic BRCA1/2-mutated breast cancer

International guidelines recommend the use of PARP inhibitors for patients with metastatic HER2-negative BC with gBRCA1/2m, who were pretreated with chemotherapy in the neoadjuvant, adjuvant or metastatic setting [10]. Only 5-10 % of BC are presenting gBRCA1/2 mutations and the current clinical usability of PARP inhibitors is limited so far to this population [11]. This raises the question whether PARP inhibitors are similarly effective in patients with somatic BRCA1/2m HER2-negative locally advanced or metastatic BC. Somatic BRCA1/2m were detected in circulating cell-free DNA (cfDNA) in 13.5 % of patients with metastatic BC and preclinical models have shown that pathogenic somatic BRCA1/2 mutations are sensitive to the PARP inhibitor talazoparib [12].

An ongoing multicenter, single-arm, phase II study (NCT03990896) has been

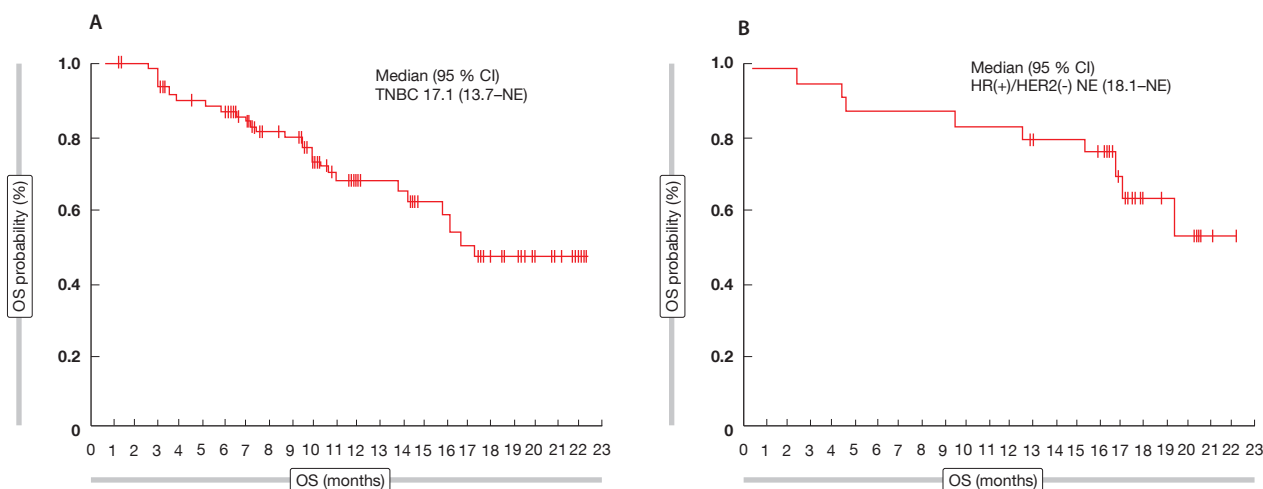


Figure 1: Median OS in the TNBC (A) and the HR+ (B) cohorts. Data cut-off October 9, 2020

initiated with the aim of evaluating the efficacy of talazoparib in patients with somatic *BRCA1/2m* metastatic BC detectable in cfDNA [13]. Eligible patients may have TNBC (with ≥ 1 prior CT) or HR+/HER2- BC (with ≥ 1 prior hormone therapy). Patients who received platinum therapy as neoadjuvant or adjuvant treatment, will have to observe at least a 6-month interval before being eligible for this trial. Patients must have adequate organ function, ECOG performance status ≤ 2 and should be PARP inhibitor naive. Patients receive talazoparib (1mg daily) until disease progression or intolerability; additionally, they undergo serial imaging using chest/abdomen/pelvis CT and bone scan at baseline and every twelve weeks, and as well as cfDNA analysis every four weeks. PFS by RECIST v1.1 was defined as the primary endpoint, while secondary endpoints include objective response rate (ORR) and safety assessed according to NCI CTCAE v5.0. Currently, two patients are completing screening at Massachusetts General Hospital (USA), where the study is already open; six more academic US centers will follow soon.

Durable clinical activity of pamiparib in HER2- BC

Pamiparib is an orally administered investigational selective PARP1/2 inhibitor, which demonstrated antitumor activity and was generally well tolerated in patients with advanced solid tumors [2, 4]. Preclinical models showed a good bioavailability and blood-brain pene-

tration [14]. A single-arm, open-label, multi-center Chinese phase II study (NCT03575065) was designed to assess the efficacy and safety of pamiparib in patients diagnosed with locally advanced or metastatic HER2-negative BC, with deleterious or suspected deleterious gBRCA1/2m TNBC or HR+/HER2-, who received ≤ 2 prior line of chemotherapy [15]. Patients received pamiparib 60 mg orally twice daily in 28-day cycles. The primary endpoint of the trial was ORR per RECIST v1.1 assessed by an independent review committee (IRC); secondary endpoints included investigator-assessed OR (INV-ORR), DOR, best overall response (BOR), PFS, clinical benefit rate (CBR), disease control rate (DCR) and OS, as well as safety and tolerability.

Out of 88 patients enrolled, 76 cases (55 in TNBC cohort and 21 in HR+ cohort) had measurable disease at baseline. The median age of patients was 46 years (range 27-67); 48 % were previously treated with platinum. The median study follow-up was 13.8 months (TNBC cohort: 10.9 months, HR+ cohort: 18.5 months). In the TNBC cohort, treatment with pamiparib demonstrated a confirmed ORR of 38.2 % (95 % CI: 25.4–52.3) and responses lasted for a median of seven months (95 % CI: 3.9–not estimable), while median PFS reached 5.5 months (95 % CI: 3.7–7.3) and median OS 17.1 months (95 % CI: 13.7–not estimable) (**Figure 1A**).

In the HR+ cohort, median ORR amounted to 61.9% (95 % CI: 38.4–81.9), median DOR was 7.5 months (95 % CI: 5.6–14.8), median PFS attained 9.2

months (95 % CI: 7.4–11.9) and survival data had not reached maturity at the time of the analysis (not reached; 95 % CI 18.1– not estimable) (**Figure 1B**). Four patients achieved a complete response (CR), including three in the TNBC cohort and one patient in the HR+ cohort. Overall, 18 patients in the TNBC cohort and twelve patients in the HR+ cohort experienced a partial response (PR). As assessed by IRC, 72.7 % of patients (95 % CI: 59.0–83.9) in the TNBC cohort and 90.5 % (95 % CI: 69.6–98.8) in the HR+ cohort achieved disease control. Additionally, a CBR of 43.6 % (95 % CI: 30.3–57.7) and of 71.4 % (95 % CI: 47.8–88.7) was reached in the TNBC- and HR+ cohorts, respectively.

Pamiparib was generally well tolerated, with treatment-emergent adverse event (TEAEs) leading to dose interruption in two patients (2.3 %) and to reduction in 57 patients (64.8 %). The most common \geq grade 3 TEAEs were hematologic events, including anemia (in 39.8 % of patients), decreased neutrophil count (29.5 %) and decreased white blood cell count (21.6 %). The encouraging data obtained in this phase 2 study suggested that pamiparib might be a feasible and tolerable treatment strategy for this population.

TBCRC 050: niraparib combined with trastuzumab

HER2 is overexpressed in around 20–30 % of BC tumors [16]. In addition to its role in DNA damage repair, PARP1 has also been implicated in other cellular functions including co-activation of

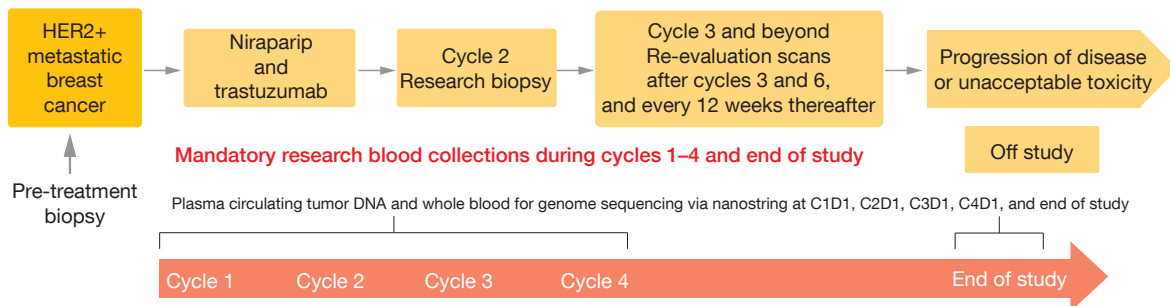


Figure 2: TBCRC 050 study design: niraparib in combination with trastuzumab in patients with metastatic HER2-positive breast cancer

genes such as NF-κB, which regulate tumor proliferation and HER2 drug resistance. It has been shown previously that the sensitivity against PARP inhibitors observed in HER2-positive BC cells may be due to elevated PARP1 expression [17]. In preclinical models, through the inhibition of NF-κB signaling, PARP inhibitors induced apoptosis independently of a DNA repair deficiency.

The TBCRC 050 trial is a multicenter, single-arm, phase Ib/II clinical study currently investigating the maximum tolerated dose and efficacy of the PARP inhibitor niraparib (200 mg orally) in combination with the anti-HER2 monoclonal antibody trastuzumab (6mg/kg, cycle 1 loading dose of 8 mg/kg) in patients diagnosed with locally advanced or metastatic unresectable HER2-positive BC (**Figure 2**) [18]. Eligible patients must have a measurable disease per RECIST v1.1 criterion, have already progressed under at least one prior HER2-

targeted therapy, present a good performance status (ECOG PS 0-1) and a LVEF (left ventricular ejection fraction) $\geq 50\%$ by ECHO or MUGA, and have adequate bone-marrow, renal and liver functions. Patients initially treated with PARP inhibitors or having a concurrent endocrine therapy (for ER+/HER2+ patients) or having a known gBRCA1/2 BC are not eligible. The recruitment of patients with stable disease as well as treated CNS (central nervous system) metastases and/or carcinomatous meningitis is allowed. The primary objectives are to assess the dose-limiting toxicity (DLT) of this combined therapy, as well as the ORR. Blood and tissue biomarkers are collected to assess clinical benefit and to predict therapy response. Enrollment started in February 2021; this trial intends to recruit 40 patients in seven participating US sites.

Synergy between anlotinib and sintilimab in cervical cancer

Cervical cancer is the fourth most common malignant disease in women with over 600,000 new diagnoses (6.5%) per year worldwide and accounting for approximately 340,000 deaths (4th place) because of cancer yearly in this population [19]. Locally advanced or metastatic cervical cancer are associated with a higher risk of recurrence [20]. Standard of care for patients with metastatic, recurrent, or persistent cervical cancer in the first-line setting is platinum-based chemotherapy with the option of adding the antiangiogenic agent bevacizumab; few treatment options exist in case of failure of this standard regimen [21]. As most cervical cancers have a viral etiology, which impairs the immune system, immune checkpoint inhibitors (CPIs) combined to other agents appears to be a promising strategy [20].

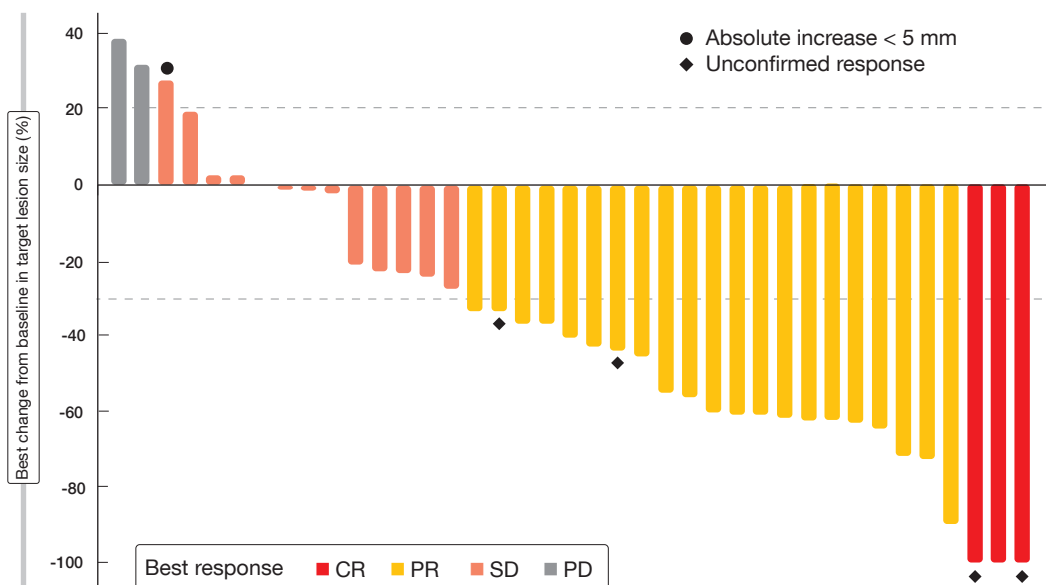


Figure 3: Best response obtained following the combination therapy of anlotinib plus sintilimab

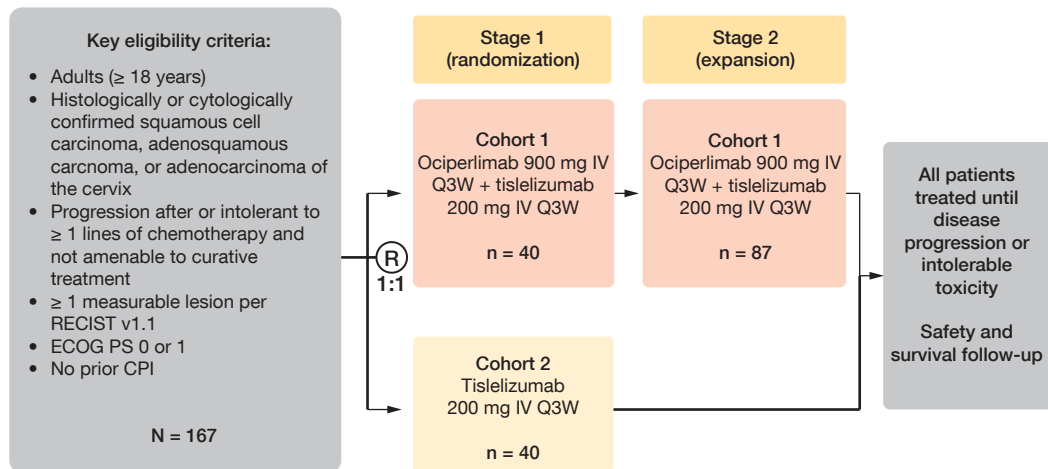


Figure 4: Study design of AdvanTIG-202 study

At the virtual ASCO 2021 meeting, Xu et al. presented the results of a new therapy combining anlotinib – a multi-target tyrosine kinase inhibitor inhibiting tumor angiogenesis and proliferative signaling – with sintilimab – a monoclonal antibody against programmed cell death-1 (PD-1) [22]. This single-arm, phase II Chinese study (ChiCTR1900023015) was conducted in patients with recurrent advanced cervical cancer to investigate the efficacy and safety of anlotinib plus sintilimab. Eligible patients should have received at least one prior platinum-based chemotherapy, have a good performance status (ECOG 0-1) and their tumor should show more than 1% PD-L1 expression. Anlotinib was administered orally (10mg/day, d1-14, 21 days per cycle) and sintilimab intravenously (200mg once every 3 weeks). The primary endpoint was ORR, while DCR, PFS, OS and safety were the secondary endpoints.

In total, 42 patients with a median age of 52 years (range, 47-58) were recruited. Among the 39 evaluable patients, objective response occurred in 61.5% of patients (95% CI, 44.9-75.9) and DCR was 94.9% (95% CI, 80.7-98.8). At the time of the analysis, the median PFS had not been reached yet. Three patients (8%) achieved a CR and 21 (54%) a PR, while 13 patients (33%) had a stable disease (SD) (Figure 3). The most common adverse events (AEs) experienced by the patients were grade 1 or 2. Grade 3 AEs were hypertension (in 4.8% of patients), hyponatremia (4.8%), immune pneumonia (2.4%) and immune myocarditis (2.4%); no AEs grade 4 were observed. The authors pointed out that, according to the presented data, anlotinib plus sintilimab might represent a potential new treatment option with manageable safety profile in patients with recurrent ad-

vanced cervical cancer; they announced more data to be presented in the future.

AdvantIG-202: a novel combination in cervical cancer

Considering the elevated rate of PD-L1 expression in up to 80% of cervical cancers [23], immune CPIs such as PD-1/PD-L1 inhibitors might be a novel therapeutic choice to improve clinical outcomes of patients with recurrent and/or metastatic cervical cancer. However, recent studies showed only moderate efficacy in this population [24-26]. Dual targeting of tumors with anti-TIGIT and anti-PD1 monoclonal antibodies might be an effective strategy to improve the clinical benefit of checkpoint inhibition. TIGIT (T-cell immunoreceptor with immunoglobulin and immunoreceptor tyrosine-based inhibition motif domain) is a co-inhibitory, immune checkpoint

REFERENCES

- Lickliter J et al., Dose Escalation/Expansion Study to Investigate the Safety, Pharmacokinetics, Food Effect, and Antitumor Activity of BGB-290 in Patients with Advanced Solid Tumors. *Ann Onc* 2017; 28 (suppl_5): v122-v141.
- Lupo B et al., Inhibition of poly(ADP-ribose)ylation in cancer: old and new paradigms revisited. *Biochim Biophys Acta* 2014; 1846(1): 201-15.
- Cortesi L et al., An Overview of PARP Inhibitors for the Treatment of Breast Cancer. *Target Oncol* 2021; 16(3): 255-282.
- Xu B et al., Pamiparib dose escalation in Chinese patients with non-mucinous high-grade ovarian cancer or advanced triple-negative breast cancer. *Cancer Med* 2021; 10(1): 109-118.
- Litton JK et al., Talazoparib in Patients with Advanced Breast Cancer and a Germline BRCA Mutation. *N Engl J Med* 2018; 379(8): 753-763.
- Hoy SM, Talazoparib: First Global Approval. *Drugs* 2018; 78(18): 1939-1946.
- SmPC talazoparib Available from: https://www.ema.europa.eu/en/documents/product-information/talzenna-epar-product-information_en.pdf.
- Ettl J et al., Poster presented at SABCS virtual symposium 2020, San Antonio, Texas.
- Ettl J et al., Characterization of long-term responders following treatment with talazoparib (TALA) or physician's choice of chemotherapy (PCT) in the phase 3 embraca trial. *J Clin Oncol* 2021; 39(suppl 15): abstr 1029.
- NCCN, Breast Cancer. 2021; Available from: <https://www.nccn.org/guidelines/guidelines-detail?category=1&id=1419>.
- Exman P et al., Evidence to date: talazoparib in the treatment of breast cancer. *Oncotargets Ther* 2019; 12: 5177-5187.
- Vidula N et al., Tumor Tissue- versus Plasma-based Genotyping for Selection of Matched Therapy and Impact on Clinical Outcomes in Patients with Metastatic Breast Cancer. *Clin Cancer Res* 2021; 27(12): 3404-3413.
- Vidula N et al., Phase II multicenter study of talazoparib for somatic BRCA1/2 mutant metastatic breast cancer. *J Clin Oncol* 2021; 39(suppl 15): abstr TPS1110.
- Xiong Y et al., Pamiparib is a potent and selective PARP inhibitor with unique potential for the treatment of brain tumor. *Neoplasia* 2020; 22(9): 431-440.
- Sun T et al., A phase 2 study of pamiparib in the treatment of patients with locally advanced or metastatic HER2-negative breast cancer with germline BRCA mutation. *J Clin Oncol* 2021; 39(suppl 15): abstr 1087.
- Mitri Z et al., The HER2 Receptor in Breast Cancer: Pathophysiology, Clinical Use, and New Advances in Therapy. *Chemotherapy Research and Practice* 2012; 2012: 743193.
- Stanley J et al., PARP1 and phospho-p65 protein expression is increased in human HER2-positive breast cancers. *Breast Cancer Research and Treatment* 2015; 150(3): 569-579.

receptor, which is upregulated on T-cells and natural killer (NK) cells in various tumor cells [27]. Ociperlimab is a novel investigational anti-TIGIT monoclonal antibody. Tislelizumab - a human IgG4 monoclonal antibody binding to and blocking PD-1 receptor expressed on activated immune cells - has been approved in China in December 2019 and is involved in a broad clinical program combining various anti-cancer agents [28].

The multicenter, open-label, randomized, phase II study AdvanTIG-202 (NCT04693234) aim to investigate the

clinical benefit of the addition of ociperlimab to tislelizumab. This trial will enroll in around 100 centers in Asia approximately 167 patients with cervical cancer (squamous cell carcinoma, adenosquamous carcinoma or adenocarcinoma) who progressed after at least one prior line of chemotherapy for recurrent or metastatic disease [22]. In Part 1, 80 patients will be randomized (1:1) to receive either ociperlimab (900 mg intravenously [IV]) in combination with tislelizumab (200 mg IV) threeweekly, or tislelizumab monotherapy (same dose) in Arm 2, until disease

progression, unacceptable toxicity, or withdrawal of consent (**Figure 4**). In Part 2, Arm 1 will be expanded by 87 additional patients whose tumors are evaluable for PD-L1 expression. ORR per RECIST v1.1 according to IRC constitutes the primary endpoint, while secondary endpoints include investigator-assessed ORR, DOR, DCR, PFS, time to response (TTR), CBR, OS, safety, and tolerability; the exploratory endpoints are health-related quality of life (HR-QoL), as well as the association of biomarkers with patient prognosis and response, or tumor resistance. ■

REFERENCES

- 18 Stringer-Reasor EM et al.**, Trial in progress: A phase 1b/2 study of the PARP inhibitor niraparib in combination with trastuzumab in patients with metastatic HER2+ breast cancer (TB-CRC 050). *J Clin Oncol* 2021; 39(suppl 15; abstr TPS1098).
- 19 Sung H et al.**, Global Cancer Statistics 2020: GLOBOCAN Estimates of Incidence and Mortality Worldwide for 36 Cancers in 185 Countries. *CA Cancer J Clin* 2021; 71(3): 209-249.
- 20 Cohen AC et al.**, Novel Therapeutics for Recurrent Cervical Cancer: Moving Towards Personalized Therapy. *Drugs* 2020; 80(3): 217-227.
- 21 Redondo A et al.**, Primary results from CECILIA, a global single-arm phase II study evaluating bevacizumab, carboplatin and paclitaxel for advanced cervical cancer. *Gynecol Oncol* 2020; 159(1): 142-149.
- 22 Wu L et al.**, AdvanTIG-202: A phase 2 study investigating anti-TIGIT monoclonal antibody ociperlimab plus anti-PD-1 monoclonal antibody tislelizumab in patients with previously treated recurrent or metastatic cervical cancer. *J Clin Oncol* 2021; 39(suppl 15; abstr TPS5595).
- 23 Duranti S et al.**, Role of Immune Checkpoint Inhibitors in Cervical Cancer: From Preclinical to Clinical Data. *Cancers (Basel)* 2021; 13(9).
- 24 Liu Y et al.**, PD-1/PD-L1 Inhibitors in Cervical Cancer. *Front Pharmacol* 2019; 10: 65.
- 25 Chung HC et al.**, Efficacy and Safety of Pembrolizumab in Previously Treated Advanced Cervical Cancer: Results From the Phase II KEYNOTE-158 Study. *J Clin Oncol* 2019; 37(17): 1470-1478.
- 26 Naumann RW et al.**, Safety and Efficacy of Nivolumab Monotherapy in Recurrent or Metastatic Cervical, Vaginal, or Vulvar Carcinoma: Results From the Phase I/II CheckMate 358 Trial. *J Clin Oncol* 2019; 37(31): 2825-2834.
- 27 Harjunpää H et al.**, TIGIT as an emerging immune checkpoint. *Clin Exp Immunol* 2020; 200(2): 108-119.
- 28 Lee A et al.**, Tislelizumab: First Approval. *Drugs* 2020; 80(6): 617-624.

Anti-PD-1 compounds targeting MSI-H/dMMR tumors

Keynote-158: an update of pembrolizumab in MSI-H/dMMR solid tumors

Accurate and timely repair of DNA is essential for maintaining genetic stability [1]. Microsatellites are repetitive DNA sequences and particularly prone to replication errors that are normally repaired by the mismatch repair system [2]. Mismatch repair-deficient tumors (dMMR) harbor many mutations in microsatellites, resulting in high levels of microsatellite instability (MSI-H) [3]. MSI-H/dMMR tumors are immunogenic, triggering the upregulation of immune checkpoint proteins such as pro-

grammed cell death protein 1 (PD-1); those tumors have been recently shown to be responsive to PD-1 blockade [4, 5]. Based on the findings of the KEYNOTE-158 study, the anti-PD-1 antibody pembrolizumab was the first immune checkpoint inhibitor (CPI) approved in 2017 for the treatment of unresectable or metastatic MSI-H/dMMR solid tumors following progression on prior standard therapy [3, 6]. KEYNOTE-158 trial (NCT02628067) was a multi-cohort, open-label, non-randomized phase II study which evaluated pembrolizumab in pan-tumor patients enrolled from 81 study centers across 21 countries worldwide [7]. Among all cohorts, the study demonstrated a clinical

benefit for 233 previously treated MSI-H/dMMR patients with solid tumors: an overall response rate (ORR) – the primary endpoint according to RECIST v1.1 and assessed by independent central radiologic review – of 34.3 %, a median progression free survival (PFS) of 4.1 months, and a median overall survival (OS) of 23.5 months [3].

At the virtual ASCO 2021 meeting, Maio et al. presented an additional 22-month follow-up of the KEYNOTE-158 trial in MSI-H patients with advanced non-colorectal solid tumors (cohort K) [8]. MSI-H/dMMR status was evaluated locally from a tumor tissue sample and defined as ≥ 1 of 4 MMR proteins absent by immunohistochem-

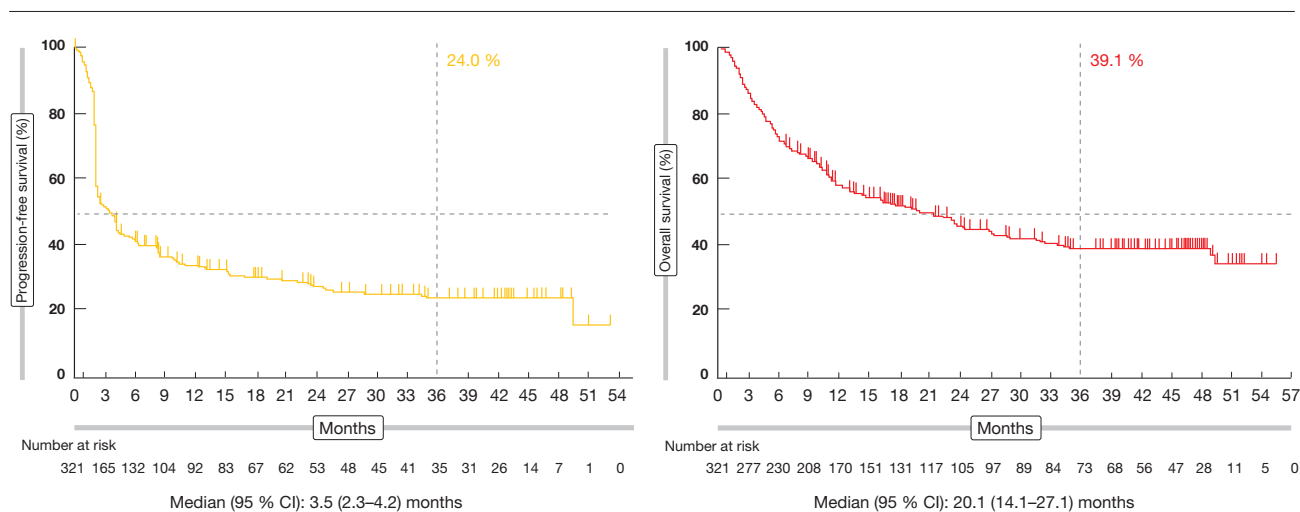


Figure 1: Updated PFS and OS Kaplan-Meier curves of KEYNOTE-158 (cohort K)

istry (IHC) or as ≥ 2 allelic loci size shifts of 5 microsatellite markers by polymerase chain reaction (PCR). Eligible patients received pembrolizumab (200 mg once every three weeks) for up to two years or until disease progression, unacceptable toxicity, investigator decision, or withdrawal of consent. Secondary endpoints included duration of response (DoR), PFS, OS, safety, and tolerability.

The cohort K included multiple tumor types, like endometrial (22.5%), gastric (14.5%), small intestine (7.4%), ovarian (7.1%), cholangiocarcinoma (6.3%), and pancreatic cancer (6.3%). Out of the 351 enrolled patients in this cohort, 27 (8.4%) had a confirmed complete response (CR), 72 (22.4%) had a partial response (PR), and 61 (19.0%) had a stable disease (SD). The ORR among the 321 eligible patients was 30.8% (95% CI, 25.8-36.2). Overall, 70.1% of patients had a continued response at 36 months. The median PFS was 3.5 months (95% CI, 2.3-4.2) and the estimated 36-month PFS rate attained 24.0%. At the time of analysis, median OS was 20.1% (95% CI, 14.1-27.1) and the estimated 36-month OS rate amounted to 39.1% (**Figure 1**).

The safety profile was consistent with previous analyses. Treatment-related adverse events (TRAEs) occurred in 64.7% of patients; 12.0% experienced TRAEs grade ≥ 3 . The most common AEs in 5% or more of patients were pruritus (14.5%), fatigue (12.3%), and diarrhea (11.7%). Immune mediated AEs and infusion reactions occurred in 20.2% of patients (in 4.8% with grade ≥ 3) and led to death in two patients be-

cause of myocarditis and Guillain-Barré syndrome.

Pembrolizumab demonstrated a maintained clinical benefit and a manageable safety profile in a heavily pretreated study population with advanced MSI-H/dMMR non-colorectal cancer.

Tislelizumab: a novel treatment option for solid tumors

Tislelizumab is a uniquely designed humanized immunoglobulin G4 (IgG4) monoclonal antibody with high affinity and binding specificity for PD-1 [9] as well as high antitumor activity in patients with solid tumors, including MSI-H/dMMR solid tumors. This anti-PD-1 antibody was engineered to minimize the binding to the Fc γ receptor (Fc γ R) on macrophages, which might be a potential strategy to circumvent resistance to anti-PD-1 therapy through the abrogation of the antibody-dependent cellular phagocytosis (ADCP) [9]. In early phase studies, Tislelizumab showed a good tolerability and antitumor activity against multiple solid tumors [10-12]. In 2019, tislelizumab was approved in China for patients with relapsed or refractory Hodgkin's lymphoma after at least a second-line chemotherapy [13]. Tislelizumab is being currently evaluated in several global pivotal trials in a wide range of tumors, including esophageal squamous cell carcinoma, hepatocellular carcinoma, and non-small cell lung cancer [13].

This single-arm, non-randomized, open-label, multicenter, phase II study investigated the efficacy and safety of ti-

slelizumab in patients with previously treated, locally advanced unresectable or metastatic MSI-H/dMMR solid tumors, including colorectal cancer (CRC) (NCT03736889) [14]. Adult patients with at least one measurable lesion according to RECIST v1.1, who received or refused prior cancer therapy regimen(s) for advanced disease, were treated with tislelizumab (200 mg intravenously three-weekly) until disease progression, unacceptable toxicity, or withdrawal. The primary endpoint was ORR as assessed by independent review committee (IRC); optionally, patients were able to continue tislelizumab monotherapy after an investigator-assessed radiological progression. Time to response (TTR), disease control rate (DCR), DoR, as well as safety and tolerability, were the secondary study endpoints.

Among the 80 patients enrolled, 74 (median age, 53 years; range, 19-75) were included in the primary efficacy analysis set. In total, 56.8% of them were male and almost all patients had metastatic disease. Overall, 62.2% of patients suffered from CRC, while 17.6% had endometrial cancer, 10.8% gastric/gastroesophageal junction (GI/GEJ) cancer, 4.1% small bowel adenocarcinoma and 5.4% another type of cancer. The median number of prior therapy regimens was two (range, 0-7). Among all tumor types, tislelizumab monotherapy resulted in an ORR of 45.9% (95% CI, 34.3-57.9; $p < 0.0001$) after a median follow-up of 11.8 months. A high rate of disease control (DCR, 71.6%) was shown with tislelizumab treatment across all tumor entities (4 CRs, 30 PRs

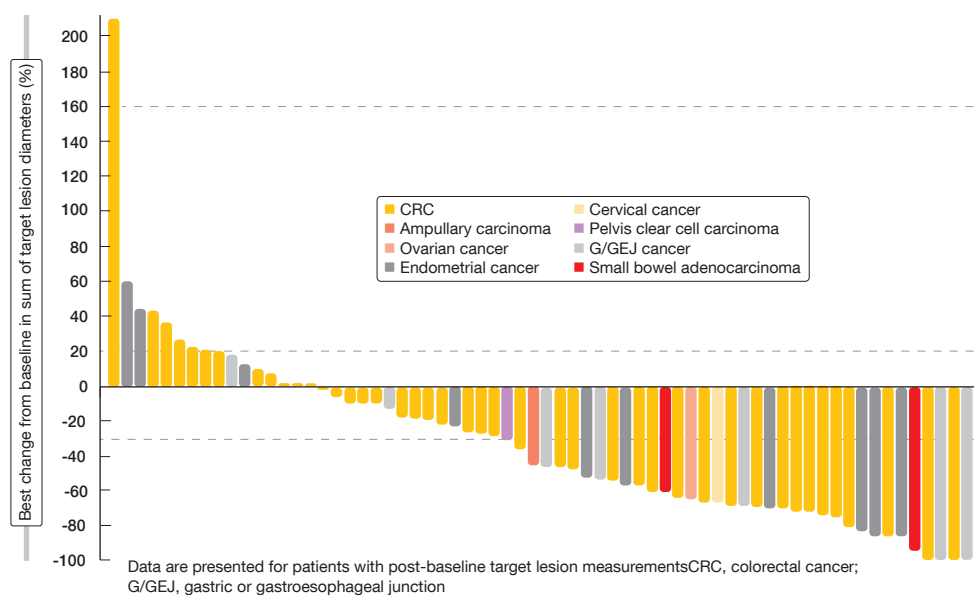


Figure 2: Best change in target lesion size from baseline by independent review committee (IRC)

and 19 SDs). The clinical benefit rate was 52.7 % and 71.6 % of patients reached a disease control. The observed ORR amounted 39.1 % (95 % CI, 25.1-54.6; 2 CRs, 16 PRs and 15 SDs) in CRC patients ($n = 46$) and 57.1 % (95 % CI, 37.2-75.5; 2 CRs, 14 PRs and 4 SDs) in non-CRC patients ($n = 28$). A reduction of target lesion size compared to baseline was reported in seven out of eight enrolled tumor types (**Figure 2**). Median DoR, PFS and OS have not been reached yet. For all analyzed tumors, 12-month PFS and OS rates were respectively 59.3 % (95 % CI, 46.2-70.2) and 75.3 % (95 % CI, 62.6-84.2). No disease progression was reported in the 34 responders, while 33 responders were still on treatment and one patient started a new anti-cancer therapy at the time of analysis.

In the safety population ($n = 80$), treatment-emergent adverse events (TEAEs) grade ≥ 3 occurred in 47.5% of patients, including laboratory abnormalities in 21.3 % of them. Immune-mediated TEAEs grade ≥ 3 occurred in 5 % of patients.

Overall, Tislelizumab monotherapy showed a clinically meaningful and durable efficacy across several tumor types. This treatment was well tolerated, and no new safety signals were detected. From the researchers' point of view, tislelizumab might be a potential new treatment option for MSI-H/dMMR solid tumors.

HLX10: the upcoming treatment alternative across tumor types

Whereas MSI-H/dMMR advanced solid tumors have a poor prognosis when treated with conventional chemotherapy, they usually reach a high response to immune checkpoint inhibitors [6, 15, 16]. The investigational anti-PD-1 monoclonal antibody HLX10 - also known as serplulimab - has shown antitumor activity and a favorable safety and tolerability profile in preclinical and early clinical studies [17]. The ongoing single-arm, open-label, multicenter, phase II study (NCT03941574) evaluates the efficacy and safety of HLX10 monotherapy for the treatment of patients with histologically or cytologically confirmed unresectable or metastatic MSI-H/dMMR solid tumors who had progressed on or been intolerant to at least one prior standard therapy [18]. The patients receive an intravenous infusion of HLX10 (3 mg/kg) every two weeks for up to two years until disease progression, unacceptable toxicity, or withdrawal of informed consent.

By the time of the analysis (January 9, 2021), 108 patients were enrolled and 68 subjects with confirmed MSI-H were included in the main efficacy analysis. Median age of the patients was 53 years (range, 23-72). MSI-H tumor types included CRC (77.9 %), endometrial cancer (7.4 %), and gastric cancer (5.9 %).

The most common prior treatments were oxaliplatin (83.8 %) and capecitabine (70.6 %). About 44.1 % patients were positive for programmed death-ligand 1 (PD-L1) at baseline.

After a median follow-up of 7.7 months, ORR per RECIST v1.1 - as assessed by an independent radiological review committee (IRRC) - and defined in the study protocol as the primary endpoint - achieved 38.2 % (95 % CI, 26.7-50.8; 2 CRs, 24 PRs and 20 SDs) and IRRC-DCR reached 67.6 % (95 % CI, 55.2-78.5). The ORR in the PD-L1 negative population ($n = 29$) and PD-L1 positive population ($n = 30$) amounted to 34.5 % and 46.7 %, respectively. Concerning the secondary endpoints reported, median DoR, PFS and OS were not attained, but a 12-month IRRC-assessed PFS and OS of 61.9 % (95 % CI, 49.0-72.5) and 81.2 % (95 % CI, 67.8-89.4) were respectively observed.

About half of the study population (49.1 %) experienced grade ≥ 3 TEAEs, primarily anemia (8.3 %), progressive disease (PD) (6.5 %), increased γ -glutamyltransferase (5.6 %) and intestinal obstruction (5.6 %). Immune-related adverse events (irAEs) appeared in 48.1 % of patients (grade ≥ 3 in 9.3 % of them). Altogether, three fatal cases (2.8 %; 2 PDs and 1 intestinal obstruction) possibly related to the investigational drug were reported.

The authors concluded that through its antitumor activity and its managea-

TABLE
Safety summary of the GARNET study

	Cohort A1 (N = 143)	Cohort F (N = 173)	Cohorts A1 + F (N = 316)
Safety summary, n (%)			
Any TEAE	140 (97.9)	167 (96.5)	307 (97.2)
Any-grade TRAE	100 (69.9)	119 (68.8)	219 (69.3)
Grade ≥ 3 TEAE	72 (50.3)	85 (49.1)	157 (49.7)
Grade ≥ 3 TRAE	23 (16.1)	20 (11.6)	43 (13.6)
Treatment-related SAE	15 (10.5)	13 (7.5)	28 (8.9)
Any TRAE leading to discontinuation	8 (5.6)	8 (4.6)	16 (5.1)
TRAE leading to death ^a	0	2 (1.2)	2 (0.6)
Grade ≥ 3 TEAEs in ≥ 2 % of patients, n (%)			
Anemia	21 (14.7)	13 (7.5)	34 (10.8)
Abdominal pain	7 (4.9)	6 (3.5)	13 (4.1)
Hyponatremia	6 (4.2)	5 (2.9)	11 (3.5)
Sepsis	4 (2.8)	6 (3.5)	10 (3.2)
ALT increased	3 (2.1)	5 (2.9)	8 (2.5)
Acute kidney injury	4 (2.8)	3 (1.7)	7 (2.2)
Lipase increased	3 (2.1)	4 (2.3)	7 (2.2)
Grade ≥ 3 irTEAEs in ≥ 1 % of patients, n (%)			
ALT increased	3 (2.1)	5 (2.9)	8 (2.5)
Lipase increased	3 (2.1)	4 (2.3)	7 (2.2)
AST increased	1 (0.7)	4 (2.3)	5 (1.6)
Diarrhea	3 (2.1)	2 (1.2)	5 (1.6)
Hyperglycemia	1 (0.7)	3 (1.7)	4 (1.3)

REFERENCES

- Eso Y et al.**, Microsatellite instability and immune checkpoint inhibitors: toward precision medicine against gastrointestinal and hepatobiliary cancers. *J Gastroenterol* 2020; 55(1): 15-26.
- Cohen AC et al.**, Novel Therapeutics for Recurrent Cervical Cancer: Moving Towards Personalized Therapy. *Drugs* 2020; 80(3): 217-227.
- Marabelle A et al.**, Efficacy of Pembrolizumab in Patients With Noncolorectal High Microsatellite Instability/Mismatch Repair-Deficient Cancer: Results From the Phase II KEYNOTE-158 Study. *J Clin Oncol* 2020; 38(1): 1-10.
- Hargadon KM et al.**, Immune checkpoint blockade therapy for cancer: An overview of FDA-approved immune checkpoint inhibitors. *Int Immunopharmacol* 2018; 62: 29-39.
- Le DT et al.**, PD-1 Blockade in Tumors with Mismatch-Repair Deficiency. *N Engl J Med* 2015; 372(26): 2509-20.
- Lemery S et al.**, First FDA Approval Agnostic of Cancer Site - When a Biomarker Defines the Indication. *N Engl J Med* 2017; 377(15): 1409-1412.
- Marabelle A et al.**, Association of tumour mutational burden with outcomes in patients with advanced solid tumours treated with pembrolizumab: prospective biomarker analysis of the multicohort, open-label, phase 2 KEYNOTE-158 study. *Lancet Oncol* 2020; 21(10): 1353-1365.
- Maio M et al.**, Pembrolizumab in microsatellite instability high (MSI-H)/mismatch repair deficient (dMMR) cancers: Updated analysis from phase 2 KEYNOTE-158 study. *J Clin Oncol* 2021; 39(suppl 15; abstr 2565).
- Zhang T et al.**, The binding of an anti-PD-1 antibody to FcγRI has a profound impact on its biological functions. *Cancer Immunol Immunother* 2018; 67(7): 1079-1090.
- Desai J et al.**, Phase IA/IB study of single-agent tislelizumab, an investigational anti-PD-1 antibody, in solid tumors. *J Immunother Cancer* 2020; 8(1): e000453.
- Shen L et al.**, Tislelizumab in Chinese patients with advanced solid tumors: an open-label, non-comparative, phase 1/2 study. *J Immunother Cancer* 2020; 8(1): e000437.
- Song Y et al.**, Treatment of relapsed or refractory classical Hodgkin lymphoma with the anti-PD-1, tislelizumab: results of a phase 2, single-arm, multicenter study. *Leukemia* 2020; 34(2): 533-542.
- Lee A et al.**, Tislelizumab: First Approval. *Drugs* 2020; 80(6): 617-624.
- Li J et al.**, A phase 2 study of tislelizumab monotherapy in patients with previously treated, locally advanced unresectable or metastatic microsatellite instability-high/mismatch repair deficient solid tumors. *J Clin Oncol* 2021; 39(suppl 15; abstr 2569).
- Le DT et al.**, Mismatch repair deficiency predicts response of solid tumors to PD-1 blockade. *Science* 2017; 357(6349): 409-413.
- Overman MJ et al.**, Nivolumab in patients with metastatic DNA mismatch repair-deficient or microsatellite instability-high colorectal cancer (CheckMate 142): an open-label, multicentre, phase 2 study. *Lancet Oncol* 2017; 18(9): 1182-1191.
- Chao T et al.**, A novel anti-PD-1 antibody HLX10 study led to the initiation of combination immunotherapy. *Ann Oncol* 2019; 30(suppl 9): ix107-ix114.
- Qin S et al.**, Efficacy and safety of HLX10, a novel anti-PD-1 antibody, in patients with previously treated unresectable or metastatic microsatellite instability-high or mismatch repair-deficient solid tumors: A single-arm, multicenter, phase 2 study. *J Clin Oncol* 2021; 39(suppl 15; abstr 2566).
- Siegel RL et al.**, Cancer statistics, 2019. *CA Cancer J Clin* 2019; 69(1): 7-34.
- Kasherman L et al.**, Dostarlimab in the treatment of recurrent or primary advanced endometrial cancer. *Future Oncol* 2021; 17(8): 877-892.
- Markham A** Dostarlimab: First Approval. *Drugs* 2021.
- Berton D et al.**, Antitumor activity of dostarlimab in patients with mismatch repair-deficient/microsatellite instability-high tumors: A combined analysis of two cohorts in the GARNET study. *J Clin Oncol* 2021; 39(suppl 15; abstr 2564).

ble safety profile, HLX10 has the potential to improve patients' clinical outcomes as an effective and safe tissue-agnostic treatment.

Dostarlimab in MSI-H/dMMR tumors

Endometrial cancers (ECs) – the most commonly diagnosed gynecologic malignancy – is usually detected in early stages of the disease [19]. However, in 21 % of cases, EC has already spread to regional lymph nodes, and distant metastases are present at initial presentation in 9 % of patients [20]. Chemotherapy remains the standard treatment, despite modest efficacy; therefore, there is a high unmet therapeutic need in advanced EC [20].

Dostarlimab is a novel humanized anti-PD-1 monoclonal antibody developed for the treatment of various tumor types. Based on preliminary results of the GARNET trial (NCT02715284), dostarlimab has been recently approved in the EU and USA as monotherapy for the treatment of adult patients with dMMR recurrent or advanced EC which were progressive on or after a platinum-based regimen [20, 21].

The open-label, multicenter, single-arm phase I, ongoing GARNET study evaluates dostarlimab in patients with advanced solid malignant entities in several cohorts. Preliminary data showed a meaningful and durable clin-

ical activity of dostarlimab in dMMR EC patients [18, 20]. At ASCO 2021, an interim analysis presented the results from cohort A1 (patients with advanced or recurrent dMMR/MSI-H EC) and cohort F (patients with dMMR or POLE-mutated non-EC solid tumors) individually and combined [22]. Dostarlimab was administered at 500 mg every three weeks for the first four cycles, and thereafter at 1000 mg every six weeks until disease progression or discontinuation.

For this interim analysis, an efficacy analysis was performed for the patients who had baseline measurable disease and ≥ 6 months of follow-up in the study. Among those 209 patients in cohorts A1 + F, the median age of the patients was 63 years (A1, $n = 103$; F, $n = 106$). The cohorts A1 + F enclosed 103 patients with endometrial cancer,

69 patients with colorectal cancer, twelve patients with small-intestine cancer, as well as eight patients with gastric and gastroesophageal junction cancer and 17 patients with other non-EC tumor types. Three or more prior therapies were received by 10.7 % of patients in cohort A1, 31.1 % in cohort F, and 21.1 % in cohorts A1 + F. ORR amounted to 44.7 % (A1; 95 % CI, 34.9-54.8), 38.7 % (F; 95 % CI, 29.4-48.6), and 41.6 % (A1 + F; 95 % CI, 34.9-48.6), respectively. In total, eleven patients (10.7 %) reached a CR and 35 patients (34.0 %) a PR in cohort A1, eight CRs (7.5 %) and 33 PRs (31.1 %) in cohort F, and in total 19 CRs (9.1 %) and 68 PRs (32.5 %) in cohorts A1 + F. In combined cohorts, responses were durable (median DoR, 34.7 months; range, 2.6-35.8) and DCR was 60.3 % (range, 53.3-67.0).

Dostarlimab was well tolerated. In cohorts A1 + F, the most common grade ≥ 3 TEAEs were anemia (10.8 %), abdominal pain (4.1 %), hyponatremia (3.5 %) and sepsis (3.2 %), while immune-related TEAEs grade ≥ 3 experienced by 2.5 % of patients were increased alanine aminotransferase (ALT) lipase (2.2 %), respectively (Table). No deaths related to dostarlimab occurred.

In their conclusions, the authors reported an antitumor activity of dostarlimab in patients with different dMMR advanced or recurrent solid malignant entities, especially here in EC and non-EC cases. With mostly low-grade TREAS observed, dostarlimab showed a good tolerable safety profile across different tumor types. ■

Early insights for CPI combinations in solid tumors

Ezabenlimab combined with anti-VEGF/Ang2 inhibitor

Immunotherapy using anti-PD-1 immune checkpoint inhibitors (CPIs), which is a major therapeutic option in oncology, can potentially achieve synergistic effects once combined with targeted therapies [1]. Drugs targeting proangiogenic factors, such as VEGF and angiopoietin 2 (ANG2), can improve therapeutic responsiveness through their immunosuppressive activity in the tumor environment [1]. Combining antiangiogenic agents with CPIs may improve patient outcomes [2]. In an ongoing phase IB trial (NCT03468426), this therapeutic approach led to a manageable safety and preliminary anti-tumor activity [3].

At the virtual ASCO 2021 meeting, Hussein et al. presented data from Module C of an ongoing open-label, phase II platform trial (NCT03697304) evaluating ezabenlimab – an anti-PD-1 antibody – in combination with BI 836880 – a humanized bispecific nanobody targeting VEGF and Ang2 – in previously treated advanced solid tumors [4]. The multicohort

Cohort 1:	Locally advanced/metastatic gastric or gastroesophageal adenocarcinoma with ≥ 1 prior treatment (anti-PD-[L]1 naïve)
Cohort 2:	Any advanced/metastatic solid tumor (excluding non-squamous NSCLC or melanoma) with prior anti-PD-(L)1 treatment for ≥ 2 months, which progressed after achieving at least SD for ≥ 4 months
Cohort 3:	Advanced/metastatic solid tumors with no benefit from prior anti-PD-(L)1 treatment (SD or PD in < 4 months)
Cohort 4:	Locally advanced/metastatic microsatellite stable colorectal cancer with ≥ 1 prior treatment (anti-PD-[L]1 naïve)
Cohort 5:	Advanced metastatic microsatellite stable and mismatch repair-proficient endometrial carcinoma, which progressed after 1 line of chemotherapy (anti-PD-[L]1 naïve)

Figure 1: Cohort description of the phase II platform trial

hort study already enrolled 150 patients into five patient cohorts (Figure 1). The patients received intravenously (IV) ezabenlimab (240 mg) and BI 836880 (720 mg) ever three weeks (Q3W). The objective response rate (ORR) per RECIST v1.1 is the primary study endpoint.

Among 60 treated patients as of April 2021, 62 % of them were male (median age, 62 years) and median duration of treatment was 70 days. Overall, 77 % of patients ($n = 46$) experienced any adverse events (AEs), most of them being mild or moderate; nausea (27 %), fatigue (23 %) and hypertension (20 %) were the most

commonly reported AEs. Treatment-related adverse events (TRAEs) were observed in 47 % of patients, none of them being grade 4 or 5. Immune-related adverse events (irAEs) occurred in 7 % of patients and included rash and arthralgia (both of grade 1/G1), hypothyroidism (G2) and increased blood creatine phosphokinase (G3). Two patients had AEs that led to treatment discontinuation (G3 bile duct stone and G2 pain). Out of 33 patients with evaluable response, one had confirmed partial response (PR), 21 had stable disease and nine experienced progressive disease (PD).

TABLE
Treatment-related adverse events experienced by more than 20 % of patients treated with the combination of anti-LAG-3 plus sintilimab

	Phase Ib (n = 18)	
	All grades, n (%)	≥ Grade 3, n (%)
Any TRAE	12 (66.7)	4 (22.2)
AST increased	5 (27.8)	0
ALT increased	4 (22.2)	0
Anaemia	4 (22.2)	0
Rash	4 (22.2)	0
Bilirubin conjugated increased	1 (5.6)	1 (5.6)
Hepatic function abnormal	1 (5.6)	1 (5.6)
Hypertension	1 (5.6)	1 (5.6)
irAE	4 (22.2)	1 (5.6)
Hypothyroidism	3 (16.7)	0
Hyperthyroidism	1 (5.6)	0
Dry mouth	1 (5.6)	0
Hyperglycaemia	1 (5.6)	1 (5.6)

Listed TRAEs occurred in more than 20 % subjects, any TRAE ≥ Grade 3 and all irAEs

The authors concluded that the combination of ezabenlimab with BI 836880 showed a manageable safety profile in this population. The study is currently recruiting in USA, Canada, and UK.

Ociperlimab plus tislelizumab in advanced solid tumors

The dual targeting of ociperlimab – an anti-TIGIT inhibitor – and tislelizumab – an inhibitor of PD-1 – induced a synergistic immune cell activation and an enhanced antitumor activity in preclinical studies. This combination has been evaluated in a first-in-human phase I study AdvanTIG-105 in three Australian centers among 26 patients with advanced, metastatic unresectable solid tumors, for which standard therapy was ineffective, intolerable, or unavailable (NCT04047862). In this trial, the pharmacokinetics, the safety and the antitumor activity of tislelizumab (200 mg, IV) combined with ociperlimab (IV, dose escalation between 50 and 900 mg, every three weeks) were investigated [5].

The median age of study participants was 56 years and 42 % were male. Two patients had a partial response (PR) (one with 900 mg ociperlimab, whose treatment is still ongoing and another with 450 mg, who unfortunately showed

progression of disease after several months). The longest duration of stable disease was 54 weeks in one patient with 150 mg ociperlimab. A reduction in target lesions of more than 30 % was observed in three patients.

Overall, 96 % of patients (n = 25) experienced at least one treatment-emergent AE (TEAE) and 58 % of them (n = 15) had one immune-related TEAE or more. In the investigational group which received 900 mg of ociperlimab, three irAEs grade ≥ 3 occurred (colitis, decreased cortisol, and diabetic ketoacidosis). No dose-limiting toxicities (DLTs) were reported.

The authors concluded that this dual therapy showed a preliminary antitumor activity and was well tolerated in patients with advanced solid tumors. The recommended phase II dose is therefore 900 mg ociperlimab IV combined with 200 mg tislelizumab IV three-weekly (Q3W).

Anti-LAG-3 monotherapy or combined with sintilimab

Lymphocyte-activation gene 3 (LAG-3) is a CPI involved in the response, activation and growth of T-cells [6]. The addition of anti-LAG-3 to an anti-PD-1 inhibitor might improve synergistically the antitumoral activity. This hypothesis

was tested in a phase Ia/Ib dose-escalation study (NCT04085185) evaluating IBI110 (anti-LAG-3) and sintilimab (anti-PD-1) in patients with locally advanced, recurrent or metastatic solid tumors and presented at ASCO 2021 [7].

The dose-escalation of IBI110 alone was investigated in the phase Ia among 22 patients, while the phase Ib evaluated IBI110 plus sintilimab (200 mg, IV, Q3W) in 18 patients; a cross-over from IBI110 monotherapy to the combination group was allowed at disease progression. The study objectives were safety and tolerability, pharmacokinetics, pharmacodynamics, and antitumor activity of IBI110 according to RECIST v1.1. The median age was 61 years in both phases; both groups enrolled in majority male patients (63.6 vs 72.2 %, respectively) and the lung was the primary tumor location (54.5 vs 66.7 %, respectively). A PR was seen in three patients (1 patient with ovarian cancer in phase Ia, as well as 2 patients with small cell lung cancer and endometrial cancer in phase Ib). Five progressive patients under IBI110 monotherapy had a stable disease (SD) with the dual therapy after crossing over.

In the phase Ia, treatment-related adverse events (TRAEs) all grades were experienced by 40.9 % of patients, while grade ≥ 3 TRAEs (anemia) occurred in 4.5 % of them. In the phase Ib with the combined therapy, a higher incidence of TRAEs any grade (66.7 %) and grade ≥ 3 (22.2 %); increased bilirubin conjugated, abnormal hepatic function and hypertension, 5.6 % each) were observed. Additionally, irAE (hyperglycemia) was experienced by one patient (5.6 %) (Table). No DLT was reported, and no adverse event led to discontinuation of the treatment in both groups. IBI110 alone or combined with sintilimab showed a preliminary antitumor activity and an acceptable toxicity.

Eftilagimod alpha plus avelumab in advanced solid tumors

Eftilagimod alpha (efti) is a soluble LAG-3 and an MHC class II antagonist involved in the activation of the antigen-presenting cells after CD8 T-cell activation. In combination with the anti-PD-1 CPI pembrolizumab, it showed already an encouraging antitumor activity by

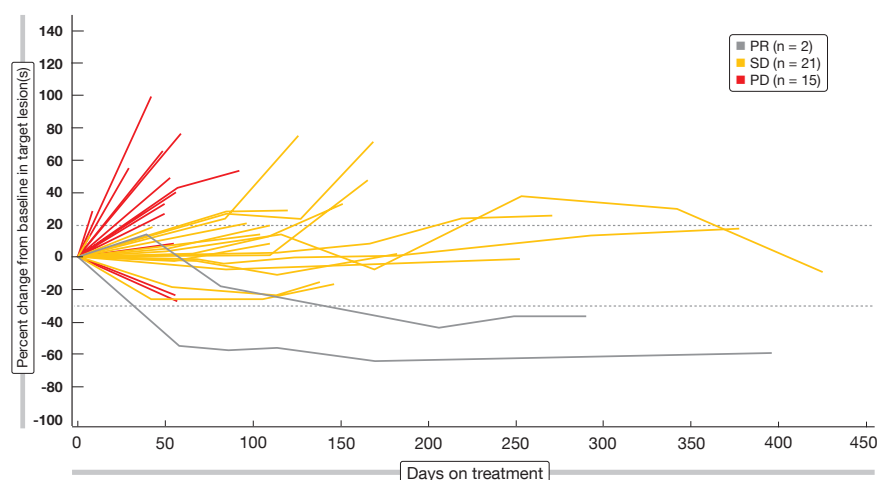


Figure 2: Spider plot: response among DLT-evaluable set (patients with measurable disease enrolled into dose escalation, patients in COM701 monotherapy expansion cohort).

good tolerability in patients with metastatic melanoma [8]. Efti is currently under investigation in a phase II study in addition to paclitaxel to treat metastatic breast cancer [9].

In the stratum D of the INSIGHT investigator-initiated (IIT) platform trial (NCT03252938), the combination of efti plus avelumab – an anti-PD-L1 inhibitor – has been evaluated in patients with histologically confirmed locally advanced or metastatic solid tumors who did not receive more than three prior lines of therapy. The twelve enrolled patients received avelumab (800 mg, IV) plus efti (6 to 30 mg, SC) Q2W for a maximum of six months, followed by avelumab maintenance therapy Q2W for a maximum of a half year further [10].

With data-cut-off of January 22, 2021, a PR as best response was obtained in five patients, one SD with clinical progression, five disease progression according to RECIST v1.1 and one clinical progression. Moreover, the disease control rate (DCR) reached 50%. Concerning the safety, among ten serious adverse events (SAEs) reported, none of them was related to the treatment. The most frequently observed grade ≥ 3 AEs were ileus (grade 3), nausea/vomiting (3), pain (3), hypokalemia (3), dysphagia (3), impaired hearing (4), sepsis (4), acute renal insufficiency (5), diffuse myocardial fibrosis (5) and urinary tract infection (3, related to avelumab).

As no unexpected AEs occurred, the researchers concluded that the combination of efti plus avelumab is feasible and safe.

Anti-PVRIG with or without nivolumab in advanced solid malignancies

COM701 is a novel first-in-class monoclonal antibody designed to block through a high affinity binding the interaction between the poliovirus receptor related immunoglobulin domain containing (PVRIG) and its ligand – PVRL2 [11]. The blockade of PVRIG induces an enhanced activation of T- and natural killer (NK) cells. At ASCO meeting 2021, Vaena et al. reported about results of an ongoing phase I study (NCT03667716) concerning the safety and tolerability, pharmacokinetics, and antitumor activity in patients with histologically confirmed locally advanced or metastatic solid tumors [12].

So far, 36 patients in monotherapy arm (A) received COM701 (0.01–20 mg/kg dose escalation, IV, Q3/Q4W). In arm B, 15 patients were administered additionally nivolumab (360 mg or 480 mg) to COM701 (0.3–20 mg/kg dose escalation) Q3/Q4W until the data-cut-off date (April 15, 2021). In the monotherapy group, the ORR was 3% and the DCR 47%, while in the combination group, these parameters amounted respectively to 13% and 67%. The Spider plot is showing the response in patients with a measurable disease (Figure 2). Overall, a CR, PR or SD was reached as best response in 52% (n = 11/21) of patients with prior treatment refractory disease and in 72% (n = 13/18) of those previously treated with a CPI.

At the maximal administered dose evaluated and chosen for the expansion cohorts (20 mg/kg COM701 alone or with 480 mg nivolumab), no DLTs were observed in both arms. Grade 3 TEAEs were experienced by 29% (n = 11/38) of patients in arm A and in 44% (n = 7/16) of those in the combination arm; they were concerning mostly ascites (8%), dyspnea (5%), nausea (3%), diarrhea (3%), vomiting (3%) and abdominal pain (3%) in arm A, as well as anemia (13%), nausea (6%) and back pain (6%) in arm B. No TEAE grade 4 was reported, but one malignant neoplasm progression (breast cancer, TEAE grade 5) was observed in arm B.

The combination of COM701 plus nivolumab had an acceptable safety profile, was well tolerated, and showed a durable antitumor activity in extensively pretreated patients.

Anti-TGF- β combined with spartalizumab in advanced solid tumors

The transforming growth factor beta (TGF- β) pathway signaling is involved in the immune regulation and plays especially a role in T-cell exhaustion, immune escape and resistance to immune checkpoint blockade [13]. Therefore, there is a scientific rationale to combine CPI with TGF- β inhibitor to improve the efficacy of the immunotherapy [14]. NIS793 is a novel anti-TGF- β monoclonal antibody and spartalizumab an anti-PD-1 inhibitor, whose safety has been already demonstrated in a first-in-human phase I study in patients with advanced solid tumors [15].

The results of a dose escalation and dose expansion first-in-man phase Ib (NCT02947165) of NIS793 first alone, than combined with spartalizumab by proven good safety have been recently presented at ASCO 2021 [16]. The safety and tolerability, as well as the determination of the recommended dose for expansion. Patients received initially NIS793 (0.3 to 1 mg/kg, Q3W) monotherapy; dose escalation continued then with NIS793 (0.3 to 30 mg/kg, Q3W) plus spartalizumab (300 mg, Q3W) or NIS793 (20 to 30 mg/kg, Q2W) plus spartalizumab (400 mg, Q4W).

In total, 60 patients were treated in the dose escalation phase and 60 more (11 in monotherapy arm and 49 in the

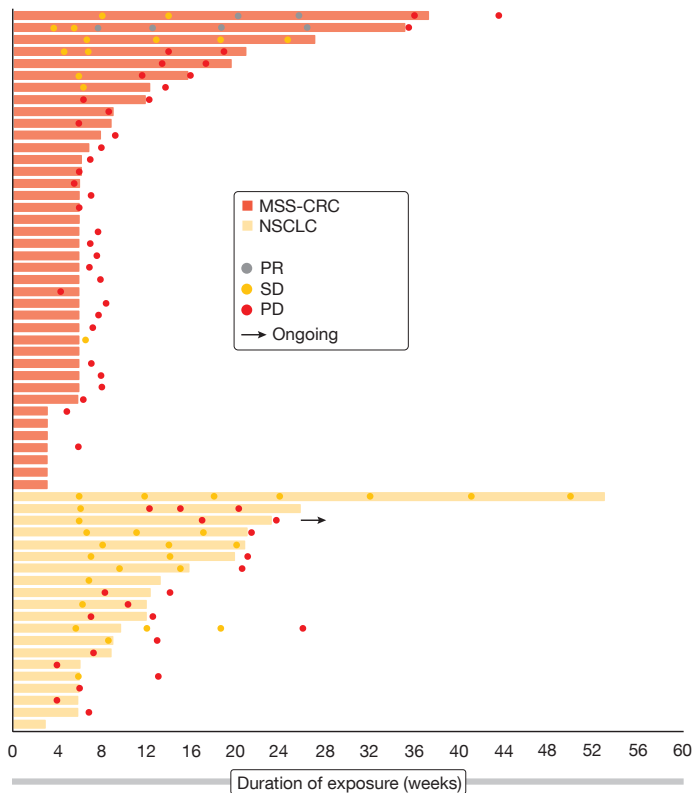


Figure 3: Duration of treatment in the expansion cohort

combination arm) in the dose expansion phase with the recommended dose (NIS793 2100 mg + spartalizumab 300 mg, Q3W) at the time of the analysis (December 1, 2020). The population was heavily pretreated, as nearly half of them had at least four prior therapies. Best response obtained were four PRs (3%) and 28 SDs (23%) - including twelve which lasted for more than four months - and 71 PDs (59%). The duration of response (DoR) attained by MSS-CRC (microsatellite stable colorectal cancer) cases (40.8% of all patients) and NSCLC (non-small cell lung cancer) cases (18.3%) is shown in **Figure 3**. Moreover, gene expression and protein analyses in tumoral tissues suggested a modulation of the TGF-β pathway.

No DLTs were observed. Most of toxicities reported were grade 1 or 2, with dermatological ones being the most common (rash and pruritus); 13 patients (11%) experienced grade 3 TRAEs, including rash (3%), hyponatremia (2%), as well as elevated lipase or amylase, adrenal insufficiency, and diarrhea (1% each). No TRAEs grade 4 or 5 were observed. Treatment-related serious adverse events were observed in 7% of patients.

The authors concluded that a preliminary antimor activity was shown with this dual therapy, which was well tolerated in the recommended dose in patients with advanced malignant entities.

CPI combinations in unselected cold tumors

Cold tumors are usually not responding to immunotherapy, as they are surrounded by cells able to suppress the immune response and keep T cells at

distance. Therefore ORRs < 10% were obtained in clinical trials with combined CPIs in this kind of tumors [17]. At ASCO 2021, an analysis performed in CPI-naïve patients with cold tumors treated between 2015 and 2021 with immune combinations was presented [18]. Clinicopathological data and antitumor activity were extracted from a prospective database.

Among the 97 patients analyzed, median age was 62 years; the most represented tumor types were microsatellite stable (MSS) colorectal cancer (61%) or ovarian cancer (14%). In total, 69% of patients received as combined treatment an anti-PD-1/L1 plus another CPI (most frequently anti-LAG3 and CD40 antagonist) (**Figure 4**). No patient achieved a response; the clinical benefit rate - defined as complete response (CR) + PR + SD for at least 4 months - was 15.3%, with 58 patients (60%) reaching a PD. Additionally, 20 patients (21%) had a hyperprogressive disease (HPD) per RECIST v1.1 as previously defined by Matos et al. [19]. The median progression-free survival (PFS) was 1.9 months (95% CI, 1.7-2.0) for the overall population and 5.9 months (95% CI, 5.4-NR) for the CBR group. The median overall survival (OS) for the overall population was 7.6 months (range, 5.9-9.5), with a benefit for patients presenting a good LIPI (lung immune prognostic index) score (12.6 vs. 6.2 months; HR, 1.9; 95% CI, 1.1-3.3; p = 0.02).

Out of 33 patients (34%) who experienced immune-mediated toxicities, four patients (12%) had grade 3 irAE (dry mouth, hypertransaminasemia, myocarditis and decreased neutrophil

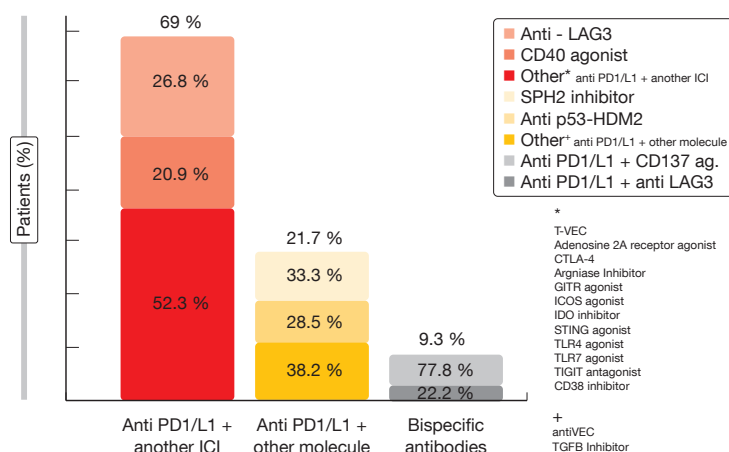


Figure 4: Anti PD-1/PD-L1 combinations

count) and 1 patient (3 %) grade 4 irAE (hyperglycemia). Overall, 33 % of patients who had PD developed irAEs.

The researchers concluded that CPI combinations showed only very limited activity in patients with unselected cold tumors and are associated with substantial risk for irAE and HPD.

Zanidatamab plus chemotherapy, with or without tislelizumab

Patients with HER2 tumors tend to develop resistance and/or relapse towards HER2-targeted therapies; therefore, those patients are characterized by a poor survival and a lack of therapeutic

responses [20, 21]. Zanidatamab is a novel anti-HER2 bispecific antibody that lead to enhanced tumor cell binding [22]; in a previously published early phase trial, Zanidatamab was well tolerated and showed antitumor activity in advanced HER2-positive tumors [23, 24]. The combination of HER2-targeting agents with chemotherapy led to improved survival [25]. Tislelizumab, which has been designed to overcome resistance to CPI, demonstrated good tolerability and antitumoral activity as monotherapy or combined with chemotherapy in advanced solid malignancies [26, 27].

At the ASCO Annual Meeting 2021, the design of a currently ongoing phase

Ib/II trial was presented (NCT02892123) [28]. In cohort 1, zanidatamab (30mg/kg or 1800 mg, IV, Q3W) plus docetaxel (75 mg/m², IV, Q3W) is evaluated as first-line therapy of patients with HER2+ metastatic breast cancer; in cohort 2, zanidatamab plus chemotherapy (Q3W) is combined to tislelizumab (200 mg, IV) in treatment-naïve patients with HER2+ advanced gastric/gastroesophageal junction adenocarcinoma (GC/GEJC). The co-primary study endpoints are safety and ORR per RECIST v1.1, while secondary endpoints include DoR, time to response, PFS, DCR, and OS. The study is intended to be conducted in twelve centers in Asia and to enroll approximately 50 patients. ■

REFERENCES

- Fukumura D et al.**, Enhancing cancer immunotherapy using antiangiogenics: opportunities and challenges. *Nat Rev Clin Oncol* 2018; 15(5): 325-340.
- Allen E et al.**, Combined antiangiogenic and anti-PD-L1 therapy stimulates tumor immunity through HEV formation. *Sci Transl Med* 2017; 9(385).
- Girard N et al.**, Phase Ib study of BI 836880, a VEGF/Ang2-blocking nanobody, in combination with BI 754091, an anti-PD-1 antibody: Initial results in patients (pts) with advanced non-small cell lung cancer (NSCLC). *J Clin Oncol* 2020; 38(suppl 15); abstr 9566.
- Hussein M et al.**, Platform trial of ezabenlimab (BI 754091), an anti-PD-1 antibody, in patients (pts) with previously treated advanced solid tumors: Combination with BI 836880, a VEGF/Ang2-blocking nanobody. *J Clin Oncol* 2021; 39(suppl 15); Abstr 2582.
- Frentzas S et al.**, AdvanTIG-105: Phase 1 dose-escalation study of anti-TIGIT monoclonal antibody ciperlimab (BGB-A1217) in combination with tislelizumab in patients with advanced solid tumors. *J Clin Oncol* 2021; 39(suppl 15); abstr 2583.
- Lythgoe MP et al.**, Gene of the month: lymphocyte-activation gene 3 (LAG-3). *J Clin Pathol* 2021; epub ahead a print.
- Zhou C et al.**, Phase Ia/Ib dose-escalation study of IBI110 (anti-LAG-3 mAb) as a single agent and in combination with sintilimab (anti-PD-1 mAb) in patients (pts) with advanced solid tumors. *J Clin Oncol* 2021; 39(suppl 15); abstr 2589.
- Atkinson V et al.**, Eftilagimod alpha, a soluble lymphocyte activation gene-3 (LAG-3) protein plus pembrolizumab in patients with metastatic melanoma. *J Immunother Cancer* 2020; 8(2).
- Dirix L et al.**, AIPAC: a Phase IIb study of eftilagimod alpha (IMP321 or LAG-3lg) added to weekly paclitaxel in patients with metastatic breast cancer. *Future Oncol* 2019; 15(17): 1963-1973.
- Goetze T et al.**, Phase I INSIGHT platform trial: Advanced safety and efficacy data from stratumD evaluating feasibility and safety of eftilagimod alpha (soluble LAG-3 protein) combined with avelumab in advanced solid tumors. *J Clin Oncol* 2021; 39(suppl 15); abstr 2518.
- Li Y et al.**, Blockade of checkpoint receptor PVRIG unleashes anti-tumor immunity of NK cells in murine and human solid tumors. *J Hematol Oncol* 2021; 14(1): 100.
- Vaena DA et al.**, COM701 with or without nivolumab: Results of an ongoing phase 1 study of safety, tolerability and preliminary antitumor activity in patients with advanced solid malignancies. *J Clin Oncol* 2021; 39(suppl 15); abstr 2504.
- Bai X et al.**, Blocking TGF- β Signaling To Enhance The Efficacy Of Immune Checkpoint Inhibitor. *Oncotargets Ther* 2019; 12: 9527-9538.
- Grauel AL et al.**, TGF β -blockade uncovers stromal plasticity in tumors by revealing the existence of a subset of interferon-licensed fibroblasts. *Nat Commun* 2020; 11(1): 6315.
- Naing A et al.**, A first-in-human phase 1 dose escalation study of spartalizumab (PDR001), an anti-PD-1 antibody, in patients with advanced solid tumors. *J Immunother Cancer* 2020; 8(1).
- Bauer T et al.**, Phase Ib study of the anti-TGF- β monoclonal antibody (mAb) NIS793 combined with spartalizumab (PDR001), a PD-1 inhibitor, in patients (pts) with advanced solid tumors. *J Clin Oncol* 2021; 39(suppl 15); abstr 2509.
- Galon J et al.**, Approaches to treat immune hot, altered and cold tumours with combination immunotherapies. *Nat Rev Drug Discov* 2019; 18(3): 197-218.
- Saavedra O et al.**, Evaluating the role of immune-checkpoint inhibitor (ICI) combinations in patients (pts) with unselected "cold" tumors enrolled in early clinical trials (CT). *J Clin Oncol* 2021; 39(suppl 15); abstr 2597.
- Matos I et al.**, Capturing Hyperprogressive Disease with Immune-Checkpoint Inhibitors Using RECIST 1.1 Criteria. *Clin Cancer Res* 2020; 26(8): 1846-1855.
- Wang J et al.**, Targeted therapeutic options and future perspectives for HER2-positive breast cancer. *Signal Transduct Target Ther* 2019; 4: 34.
- Ayoub NM et al.**, Immunotherapy for HER2-positive breast cancer: recent advances and combination therapeutic approaches. *Breast Cancer* (Dove Med Press) 2019; 11: 53-69.
- Weisser N et al.**, The Bispecific Antibody Zanidatamab (ZW25) Has Unique Mechanisms of Action and Durable Anti-Tumor Activity in HER2-Expressing Cancers. *AACR 2021* (Abstr 1005) 2021.
- Oh D et al.**, Safety, anti-tumour activity, and biomarker results of the HER2-targeted bispecific antibody ZW25 in HER2-expressing solid tumors. *Ann Oncol* 2019; 30 (suppl_9): ix22-ix29.
- Meric-Bertram F et al.**, Zanidatamab (ZW25) in HER2-positive biliary tract cancers (BTCs): Results from a phase I study. *J Clin Oncol* 2019; 39(suppl 3); abstr 299.
- Pernas S et al.**, HER2-positive breast cancer: new therapeutic frontiers and overcoming resistance. *Ther Adv Med Oncol* 2019; 11: 1758835919833519.
- Lee A et al.**, Tislelizumab: First Approval. *Drugs* 2020; 80(6): 617-624.
- Zhang T et al.**, The binding of an anti-PD-1 antibody to Fc γ RI has a profound impact on its biological functions. *Cancer Immunol Immunother* 2018; 67(7): 1079-1090.
- Lee K et al.**, Zanidatamab, an anti-HER2 bispecific antibody, plus chemotherapy with/without tislelizumab as first-line treatment for patients with advanced HER2-positive breast cancer or gastric/gastroesophageal junction adenocarcinoma: A phase 1B/2 trial-in-progress. *J Clin Oncol* 2021; 39(suppl 15); abstr TPS2656.

Esophageal cancer: taking immunotherapy one step further

In 2020, more than 604,000 new cases of esophageal cancer (EC) were diagnosed; EC was the sixth leading cause of cancer-related death worldwide [1]. Especially in Asia, the incidence of EC is high; for instance in China, its mortality rate reaches the fourth place of all deaths caused by cancer [2]. Esophageal squamous cell carcinoma (ESCC) accounted globally for approximately 85 % of all EC affected patients [3], with more than half of all ESCC cases worldwide are observed in China [4]. As most patients with ESCC are diagnosed in an advanced stage of the disease, their prognosis is poor, with an estimated 5-year survival rate of approximately 5 % [5]. Paclitaxel plus cisplatin or 5-FU plus cisplatin were the standard first-line therapy of advanced ESCC for almost two decades [6]. Considering that 1L chemotherapy leads to suboptimal overall survival (OS), alternative treatment options for this difficult-to-treat cancer with high related mortality (90 %) are scarce [1, 7].

In ESCC, PD-L1 overexpression (up to 62 %) is significantly associated with poor prognosis [8]. In previous clinical trials, the combination of an immune checkpoint inhibitor (CPI) and chemotherapy has demonstrated synergistic antitumoral activity [9]. However, only moderate improvements in terms of ORR and OS have been obtained so far

with anti-PD-1 CPI versus chemotherapy as first-line treatment in patients with advanced ESCC [10], as well as for 2L therapy in patients with recurrent, locally advanced or metastatic ESCC who progressed on or after one prior line of systemic treatment [11, 12].

Immunotherapy benefit in ESCC

In the phase III ATTRACTION-3 trial, the anti-PD-1 CPI nivolumab used as monotherapy has proven to be superior to chemotherapy in terms of OS in patients with ESCC that was refractory or intolerant to previous chemotherapy [11]. Additionally, nivolumab plus ipilimumab already showed significant antitumoral efficacy across several tumor types [13].

In the randomized, phase III CheckMate 648 study (NCT03143153), the efficacy and safety of nivolumab as front-line treatment were evaluated in patients with unresectable, advanced, recurrent, or metastatic ESCC following a 3-arm design (1:1:1) nivolumab plus chemotherapy (CT), nivolumab plus anti-CTLA-4 CPI ipilimumab, or chemotherapy alone. The treatment administered was either nivolumab (240 mg every other week [Q2W]) plus chemotherapy (fluorouracil + cisplatin Q4W), or nivolumab (3 mg/kg Q2W) plus ipili-

mumab (1 mg/kg Q6W), or chemotherapy alone until disease progression, discontinuation due to toxicity, withdrawal of consent or study end. OS and progression-free survival (PFS) according to a blinded independent central review (BICR) in patients whose tumor cells expressed at least 1 % PD-L1 were the dual primary endpoints.

The primary analysis presented at ASCO 2021 included 970 enrolled patients [14]. After a minimum of 12.9 months follow-up, compared to chemotherapy alone, the regimen nivolumab plus chemotherapy showed a significant OS benefit compared to chemotherapy (15.4 vs 9.1 months; HR, 0.54; 99.5 % CI, 0.37-0.80; $p < 0.0001$) (**Figure 1A**) and a meaningful PFS advantage (6.9 vs 4.4 months; HR, 0.65; 98.5 % CI, 0.46-0.92; $p < 0.0023$) in patients with tumor cells PD-L1 $\geq 1\%$. Similarly, median OS was significantly better in the nivolumab + ipilimumab arm compared to chemotherapy alone (13.7 vs 9.1 months; HR, 0.64; 99.5 % CI, 0.46-0.90; $p < 0.001$) (**Figure 1B**), but no PFS benefit was observed. Among patients with PD-L1 expressing tumors, the ORR reached 53 % in the nivolumab + chemotherapy arm versus 35 % in the nivolumab + ipilimumab arm versus 20 % with chemotherapy alone, while median DoR amounted to 8.4 versus 11.8 versus 5.7 months, respectively.

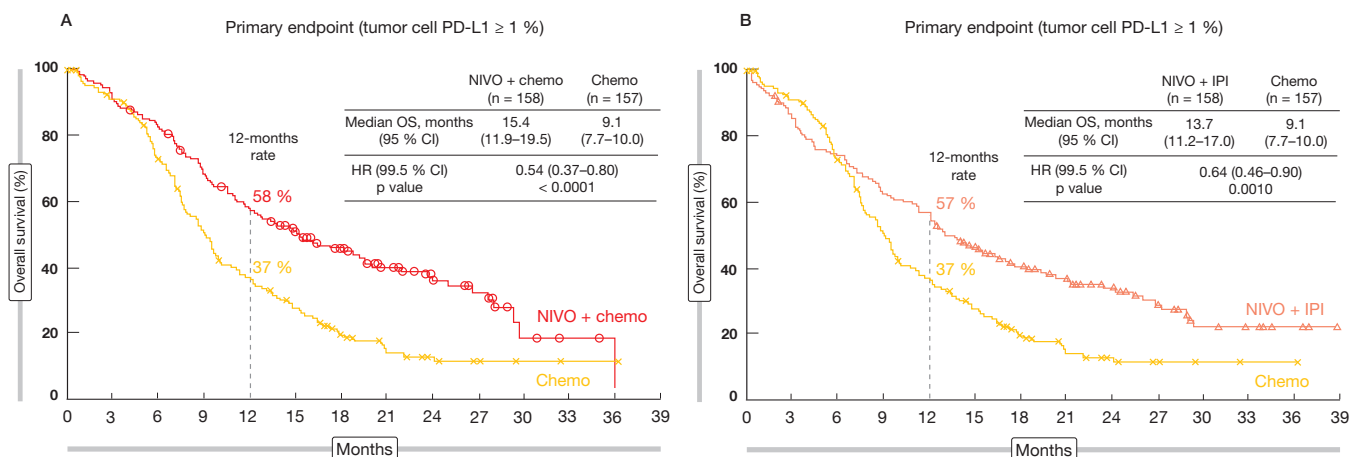


Figure 1: Overall survival curves for nivolumab plus chemotherapy vs. chemotherapy alone (A) and nivolumab plus ipilimumab vs. chemotherapy (B).

Similar findings were observed regardless of PD-L1 expression.

In terms of safety, most common any-grade treatment-related adverse events (TRAEs) ($\geq 10\%$) included nausea, decreased appetite and stomatitis in the nivolumab plus chemotherapy arm (96%), as well as in the chemotherapy (90%) arm, whereas rash, pruritus and hypothyroidism were reported with nivolumab plus ipilimumab (80%). Most selected side effects with potential immunologic etiology that require frequent monitoring/intervention experienced by study participants were grade 1 or 2; grades 3 and 4 TRAEs occurred in $\leq 6\%$ of patients across several organ categories. In comparison to previous studies with those CPIs, no new safety signals were detected.

The authors concluded that both nivolumab plus chemotherapy and the dual immunotherapy regimen are potential new 1L standards of care for patients with advanced ESCC, particularly for those with PD-L1 positive tumors.

RATIONALE 302: tislelizumab as 2L therapy of ESCC

Tislelizumab is an IgG4 monoclonal antibody against PD-1, which might avoid the development of resistance to anti-PD-1 therapy [15]. In early phase studies, the antitumoral activity of tislelizumab monotherapy was already shown in several solid tumors including ESCC [16]. Therefore, the authors hypothesized that tislelizumab might be an alternative treatment to the current chemotherapy standard.

RATIONALE 302 was a global, phase III trial (NCT03430843) that investigated the efficacy and safety of tislelizumab compared to chemotherapy in patients with histologically confirmed advanced/unresectable or metastatic ESCC, who progressed during or after a prior systemic therapy. Tislelizumab was administered at 200 mg intravenously (IV) every three weeks; the investigator-chosen therapy consisted of paclitaxel or docetaxel or irinotecan. The primary analysis of the data was presented at ASCO 2021 [17].

In total, 512 patients from 132 sites across 10 countries in Asia, Europe and North America, were randomized 1:1. The study met its primary endpoint as a significantly better median OS was ob-

served with tislelizumab compared to the chemotherapy arm (8.6 vs 6.3 months; HR, 0.70; 95% CI, 0.57-0.85; $p = 0.0001$). In patients with PD-L1 expression $\geq 10\%$ by vCPS, tislelizumab showed a clinically meaningful OS improvement – the key secondary endpoint – over chemotherapy with a 46% reduction in the risk of death (10.3 vs 6.8 months; HR, 0.54; 95% CI, 0.36-0.79; $p = 0.0006$). An OS benefit was consistently observed across all pre-defined subgroups. Compared to chemotherapy, a higher response rate was obtained with tislelizumab (ORR, 20.3 vs 9.8%) and the responders showed a more durable DoR (7.1 vs 4.0 months; HR, 0.42; 95% CI, 0.23-0.75).

Overall, 19% of tislelizumab-treated patients experienced grade ≥ 3 TRAEs versus 56% in the group who received chemotherapy. TRAEs leading to treatment discontinuation amounted to 7% with tislelizumab and 14% with chemotherapy. No new safety signals were detected.

As tislelizumab showed a statistically significant and clinically meaningful improvement in OS compared to chemotherapy, as well as a better safety profile, the researchers concluded that it might be a potential new standard second-line therapy option for patients with advanced/unresectable or metastatic ESCC.

Synergy between immunotherapy and chemotherapy in ESCC

During a presentation at ASCO 2021 [18], the first author Rui-hua Xu spoke about a potential synergistic effect between immunotherapy and chemotherapy in patients with advanced or metastatic ESCC. The efficacy and safety of camrelizumab – an anti-PD-1 monoclonal antibody that already showed promising antitumoral activity in 2L ESCC (ESCOR trial) [19] – was thus evaluated in the phase III ESCORT-1st study (NCT03691090) as first-line therapy for advanced or metastatic ESCC patients. Study patients received either camrelizumab (200 mg) plus chemotherapy (paclitaxel and cisplatin for up to 6 cycles) or only the chemotherapy doublet IV Q3W. The co-primary endpoints were PFS assessed per IRC (independent review committee) and OS.

The first interim analysis presented the data of 596 eligible patients (median age of 62 years; mostly male patients) from 60 Chinese hospitals, who were randomized 1:1 to each arm. With a median follow-up of 10.8 months, a statistically significant median OS improvement was observed when camrelizumab was added to the dual chemotherapy regimen (15.3 vs 12.0 months; HR, 0.70; 95% CI, 0.56-0.88; $p = 0.001$). Concerning the median IRC-PFS, camrelizumab plus chemotherapy reduced the risk or progression or death by 44% compared to chemotherapy alone (6.9 vs 5.6 months; HR, 0.56; 95% CI, 0.46-0.68; $p < 0.001$). Both OS and PFS benefits were observed in nearly all analyzed subgroups. In the immune-chemotherapy arm compared to the control arm, a higher response rate (ORR, 72.1 vs 62.1%; CRs, 20 vs 11; PRs, 195 vs 174; SDs, 57 vs 80) and a longer DoR (7.0 vs 4.6 months) were observed.

A similar incidence of grade ≥ 3 TRAEs was observed in both patient groups; serious AEs occurred in 30.2% of patients in the investigational arm and 23.2% in the control arm. Camrelizumab plus chemotherapy showed a manageable safety profile and no new safety signals were identified.

Based on those findings, the author concluded that camrelizumab combined with paclitaxel plus cisplatin might be a new promising 1L therapy option for those patients; he also revealed that a new drug application dossier was already submitted to the China National Medical Products Administration for the approval of the combined immunochemotherapy in this setting.

Expanded analysis of CheckMate 649 in GC/GEJC/EAC

For patients with advanced or metastatic HER2-negative gastric cancer (GC) or gastroesophageal junction cancer (GEJC), 1L chemotherapy led to limited outcome, with a median OS of less than a year [20]. In the randomized, phase III CheckMate 649 study (NCT02872116), the efficacy and safety of first-line nivolumab plus chemotherapy versus chemotherapy alone was evaluated in advanced GC/GEJC/EAC (esophageal adenocarcinoma). In this trial, eligible patients with previously

untreated, unresectable advanced or metastatic GC/GEJC/EAC – except those HER2-positive – were randomized 1:1:1 to receive either nivolumab (360 mg, Q3W or 240 mg, Q2W) plus chemotherapy (Xelox, Q3W or Folfox, Q2W) or nivolumab plus ipilimumab (Q3W x 4, then nivolumab 240 mg, Q2W) or only the chemotherapy regimen.

The first data of this trial were presented at ESMO 2020 [21]; the immunotherapy combination showed an OS superiority and a PFS benefit compared to chemotherapy alone. Based on those findings, nivolumab plus chemotherapy received FDA approval as 1L therapy for GC/GEJC/EAC in April 2021. At this year's ASCO meeting, an expanded analysis of the CheckMate 649 was presented [22].

In this updated analysis, the OS (13.8 vs 11.6 months; HR, 0.80; 95 % CI, 0.68-0.94; $p = 0.0002$) and PFS (7.7 vs 6.9 months; HR, 0.77; 95 % CI, 0.68-0.87) benefits of the immunotherapy combination over chemotherapy in all randomized patients were confirmed. To note, OS advantage was observed across multiple prespecified subgroups. A higher response was obtained in the investigational arm compared to the control arm (ORR, 58 vs 46 %; CRs, 10 vs 6; PRs, 48 vs 40; SDs, 28 vs 33); this ORR benefit was observed regardless of the PD-L1 expression status and was more durable (DoR, 8.5 vs 6.9 months, respectively).

In total, TRAEs grade 3-4 were experienced by 59 % of patients in the nivolumab plus chemotherapy group and in 44 % of those in the chemotherapy group. Concerning the HR-QoL, patients in the investigational arm showed a decreased risk of symptom deterioration on treatment compared to the patients in the control group (HR, 0.77; 95 % CI, 0.63-0.95; $p = 0.0129$).

These updated data further support this immunotherapy as first-line standard treatment in patients with advanced HER2-negative GC/GEJC/EAC.

Pembrolizumab in neoadjuvant setting in EAC patients

In patients with resectable EC or GEJC, neoadjuvant chemoradiotherapy (CRT) has been shown to improve survival [23]. Recently, adjuvant anti-PD-1

nivolumab treatment following neoadjuvant CRT has been demonstrated to be beneficial in resected EC/GEJC patients with residual disease (CheckMate 577 trial) [24]. In the Keynote-590 study, the efficacy of anti-PD-1 pembrolizumab plus chemotherapy has been proven as efficient and safe 1L treatment of EC/GEJC patients [25]. Therefore, one might hypothesize that the addition of pembrolizumab to CRT in the neoadjuvant setting may further improve the outcome of locally advanced EAC patients.

In a randomized, phase II study, patients with T2-4 or N+ non-metastatic, resectable EAC or GEJC were randomized 1:1 to receive either full-dose paclitaxel (T)/ carboplatin (C) or T/C + pembrolizumab as preoperative therapy (NCT02998268). All study patients got neoadjuvant CRT, consisting in weekly dual chemotherapy with 41.4 Gy in 23 radiotherapy fractions; in the investigational arm, pembrolizumab was additionally administered every 3rd week. Following resection, all patients received pembrolizumab for one year. The rate of major pathologic response (MPR, defined as pathologic CR or near CR [< 10 % residual disease]) was primary assessed [26].

Among the 39 enrolled patients (15 with EC or type I GEJC, 24 with type II or III GEJC), 79.5 % were male and the median age was 68 years. MPR rate was 48.7 % (95 % CI, 33.0-64.4) at the time of the analysis. Overall, 1-year OS rate were 77.5 % (95 % CI, 56.4-89.3), with a 1-year OS rate of 93.8 % (95 % CI, 63.2-99.1) in patients with MPR and 62.5 % (95 % CI, 31.5-82.6) in those without MPR. Similarly, 1-year DFS was 60.4 % (95 % CI, 39.3-76.2), with 100.0 % achieved by patients with MPR and 23.5 % without MPR (95 % CI, 5.8-47.9; $p = 0.001$). Interestingly, patients with EC showed a significantly higher MPR rate than those with GEJC (73.3 vs 33.3 %). This might be explained by a different tumor immune microenvironment in those tumor entities; indeed, EAC or GEJC type I tumors presented a greater infiltration of activated dendritic cells ($p = 0.12$), whereas GEJ tumors showed a significantly higher infiltration of activated B cells ($p = 0.02$).

Pembrolizumab plus CRT was well tolerated. Post-surgery, typical post-operative AEs – including wound dehiscence, infections, atrial fibrillation, and cardiac toxicities – were reported, while the most common toxicities of interest grade 3-4 observed were elevated liver enzymes (13.9 %), pneumonitis (11.1 %), elevated blood sugar (8.3 %) and adrenal insufficiency (2.8 %).

In resectable EC or GEJC patients, the combination of pembrolizumab plus CRT as neoadjuvant therapy, followed by pembrolizumab adjuvant treatment, was safe and more efficient than CRT alone in terms of MPR, DFS and OS. Two follow-up clinical studies are currently investigating the benefit of the addition of pembrolizumab (Keynote-975) or nivolumab (EA2174) to CRT in the neoadjuvant setting.

New doublet CPI as combined therapy for ESCC

KN046 is the first dual CPI which has been designed to block both PD-1/PD-L1 and CTLA-4 pathways simultaneously. Its efficacy and safety as monotherapy or in combination with chemotherapy is currently under evaluation in a phase II study in China. Patients with histologically or cytologically confirmed unresectable, locally advanced, recurrent, or metastatic ESCC are included in the study cohort (NCT03925870).

The preliminary results of the cohort 3 (1L therapy) were recently presented at ASCO 2021 [27]. Eligible patients are receiving KN046 (5 mg/kg) plus paclitaxel (135-175 mg/m²) and cisplatin (75 mg/m²) intravenously Q3W for four to six cycles; additionally, in patients without progressive disease, a maintenance therapy with KN046 monotherapy (Q2W) is administered until progression or unacceptable toxicity. Investigator-assessed ORR per RECIST v1.1 is the primary endpoint.

At the time of analysis, among 15 male patients (median age, 63 years; 80 % stage IV) already enrolled, twelve, who had at least one tumor assessment, entered the evaluable analysis set (EAS). The ORR was 58.3 % (95 % CI, 21.1-78.9), while the DCR amounted to 91.7 % (95 % CI, 61.5-99.8; 4 PRs, 3 unconfirmed PRs and 4 SDs). One patient had a progressive disease (PD).

The incidence of KN046-associated AEs was 80.0 %, 13.3 % of them being grade ≥ 3 TRAEs. Immune-related AEs (irAEs) of any grade were observed in

TABLE
Secondary and exploratory endpoints of the AdvanTIG-203 study

Secondary endpoints	Exploratory Endpoints
ORR by IRC	Association between exploratory biomarkers and clinical efficacy, disease status, and resistance
PFS by IRC and investigators	Biomarkers include, but are not limited to, TIGIT, CD226, CD155, CD112 and PD-L1, GEP, and TMB/gene mutation/MSI
DoR by IRC and investigators	Serum ociperlimab and tislelizumab concentrations at specified timepoints
DCR by IRC and investigators	Immunogenic responses to ociperlimab and tislelizumab
CBR by IRC and investigators	QoL, measured by EQ-5D-5L assessment
HRQoL EOTRC, QLQ-C30, and QLQ-OES18	
Type, frequency, and severity of AEs and SAEs	

53.3 % of patients; most common grade ≥ 3 irAEs experienced by 13.3 % of patients were nausea (n = 1, 6.7 %) and rash (n = 1, 6.7 %).

The study group concluded that KN046 combined to the dual chemotherapy paclitaxel plus cisplatin is an efficient and safe first-line treatment, and therefore a potential new therapeutic option for patients with advanced ESCC.

AdvanTIG-203: dual targeting in ESCC

Because of resistance mechanism, a durable outcome remains an unmet need in patients with recurrent, locally advanced, or metastatic ESCC who progressed on or after one prior line of systemic treatment. TIGIT is a co-inhibitory immune checkpoint receptor expressed on immune cells in multiple solid tumors [28]. Ociperlimab is a humanized, monoclonal antibody targeting TIGIT with a highly specific binding activity; thereby, it activates the antitumoral immune response through T-cells and natural killer cells [29]. The anti-PD-1 ti-

slelizumab has been designed to have a minimal binding to Fcγ receptor on macrophages to abolish the antibody-dependent phagocytosis, a mechanism involved in resistance to anti-PD-1 treatment [15]. The OS superiority of tislelizumab over chemotherapy in the 2L treatment of patients with advanced or metastatic ESCC was presented at this year’s ASCO meeting [17]. Moreover, a dual targeting of tumors with an anti-TIGIT and anti-PD-1 has been already shown to result in a synergistic immune cell activation in early phase studies [30].

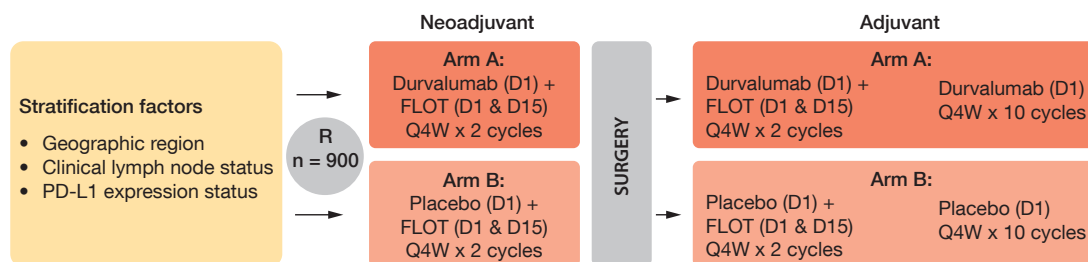
At ASCO 2021, the design of a new randomized, double-blind, phase II study named AdvanTIG-203 (NCT04732494) – which aims to evaluate the efficacy and safety of ociperlimab plus tislelizumab – was presented. This trial is currently enrolling patients with histologically confirmed unresectable, locally advanced, recurrent or metastatic ESCC, who are progressive following first-line systemic therapy and whose tumors express PD-L1 (CPS ≥ 10) [31]. This trial intends to randomize 140

patients in each study arms: in arm A, patients receive IV Q3W ociperlimab (900 mg) plus tislelizumab (200 mg), while patients in arm B receive tislelizumab plus placebo. The OS and ORR are the co-primary study endpoints; the multiple secondary and exploratory endpoints are described in the **Table**. Concerning the safety assessments, AEs, serious AEs (SAEs) and irAEs will be reported.

MATTERHORN: neoadjuvant-adjuvant durvalumab in GC/GEJC

In 2020, gastric cancer (GC) was the sixth more common cause of cancer worldwide and responsible of more than 760, 000 deaths (mortality rate of 71 %) [1]. In Western countries, neoadjuvant-adjuvant FLOT (5-fluorouracil + leucovorin + oxaliplatin + docetaxel) chemotherapy is the standard of care of resectable GC/GEJC [32]; in East Asian countries, surgery – followed by adjuvant chemotherapy and eventually preceded by perioperative chemotherapy – is the current treatment in this setting [33]. Despite improved OS outcome thanks to new treatment advances, patients with GC/GEJC have a poor prognosis, mostly due to a high recurrence rate [34]. Previous evidence suggested that the combination of an anti-PD-1 CPI and cytotoxic chemotherapy as neoadjuvant-adjuvant treatment may result in increased efficacy [35].

The randomized, double-blind, ongoing, global, multicenter, phase III MATTERHORN study (NCT04592913) evaluates FLOT chemotherapy plus neoadjuvant-adjuvant anti-PD-1 durvalumab or placebo - followed respectively by adjuvant durvalumab or placebo - in patients with histologically confirmed (stage II or higher) resecta-



FLOT: 5-fluorouracil 2600 mg/m² + leucovorin 200 mg/m² + oxaliplatin 85 mg/m² + docetaxel 50 mg/m² on days 1 and 15 Q4W
Durvalumab: 1,500 mg on day 1 Q4W

Figure 2: MATTERHORN study design

ble GC/GEJC [36]. This trial is open for enrolment and intend to enroll 900 anticancer therapy-naïve patients equally either in the investigational group (arm A) or in the control group (arm B) following the design described in **Figure 2**. The key inclusion criteria include a complete surgical resection of the primary tumor, as well as a performance status ≤ 1 . Patients who received any prior immune-mediated therapy, as well as those who have peritoneal dissemination or distant metastasis, (adeno)squamous cell carcinoma or gastrointestinal stromal tumor, will be excluded. The primary endpoint is event-free survival (EFS) assessed by

BICR and/or pathology testing; the secondary endpoints include OS, pathological complete response (pCR) rate, safety, and tolerability profile.

KEYNOTE-811 study

In this ongoing, global, randomized, double-blind, placebo-controlled, phase III study (NCT03615326), the addition of the anti-PD-1 pembrolizumab (200 mg IV Q3W) to the standard-of-care (SOC) 1L therapy (trastuzumab plus chemotherapy) was evaluated in unresectable or metastatic HER2+ G/GEJ cancer [37]. From the first 264 enrolled patients, the confirmed ORR was higher with the in-

vestigational combination compared to SOC (74.4 vs 51.9 %; 95 % CI, 11.2-33.7; $p = 0.00006$), with a CR rate of 11.3 vs 3.1 %. The addition of pembrolizumab to SOC led to a longer median DoR (10.6 vs 9.5 months with SOC). Grade 3-5 AEs were experienced by 57.1 % of patients in pembrolizumab + SOC arm versus 57.4 % with SOC; discontinuation rate was 24.4 vs 25.9 %, respectively.

Based on these results showing a durable response and a manageable safety, the triple regimen was approved by the FDA for this patient population in May 2021. ■

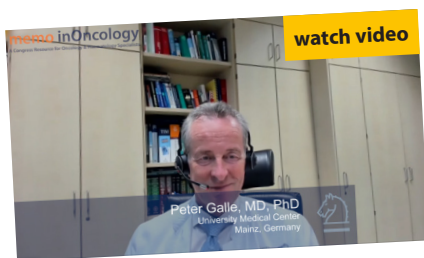REFERENCES

- Sung H et al.**, Global Cancer Statistics 2020: GLOBOCAN Estimates of Incidence and Mortality Worldwide for 36 Cancers in 185 Countries. *CA Cancer J Clin* 2021; 71(3): 209-249.
- International Agency for Research on Cancer, WHO**, Globocan. China. 2020; Available from: <https://gco.iarc.fr/today/data/factsheets/populations/160-china-fact-sheets.pdf>.
- Arnold M et al.**, Global burden of oesophageal and gastric cancer by histology and subsite in 2018. *Gut* 2020; 69(9): 1564-1571.
- Hou H et al.**, Survival of Esophageal Cancer in China: A Pooled Analysis on Hospital-Based Studies From 2000 to 2018. *Front Oncol* 2019; 9: 548.
- Howlader N SEER** Cancer Statistics Review (CSR) 1975-2016. 2020; Available from: https://seer.cancer.gov/archive/csr/1975_2016/results_merged/sect_08_esophagus.pdf.
- Lordick F et al.**, Oesophageal cancer: ESMO clinical practice guidelines. *Ann Oncol* 2016; 27(suppl 5): v50-v57.
- Moehler M et al.**, Cisplatin and 5-fluorouracil with or without epidermal growth factor receptor inhibition panitumumab for patients with non-resectable, advanced or metastatic oesophageal squamous cell cancer: a prospective, open-label, randomised phase III AIO/EORTC trial (POWER). *Ann Oncol* 2020; 31(2): 228-235.
- Wang Q et al.**, PD-L1 Expression On tumor Cells Was Associated With Unfavorable Prognosis In Esophageal Squamous Cell Carcinoma. *J Cancer* 2018; 9(12): 2224-2231.
- Baba Y et al.**, Tumor immune microenvironment and immune checkpoint inhibitors in esophageal squamous cell carcinoma. *Cancer Sci* 2020; 111(9): 3132-3141.
- Kato K et al.**, Pembrolizumab plus chemotherapy versus chemotherapy as first-line therapy in patients with advanced esophageal cancer: The phase 3 KEYNOTE-590 study. *Ann Oncol* 2020; 31(suppl 4): S1142-S1215.
- Kato K et al.**, Nivolumab versus chemotherapy in patients with advanced oesophageal squamous cell carcinoma refractory or intolerant to previous chemotherapy (ATTRACTION-3): a multicentre, randomised, open-label, phase 3 trial. *Lancet Oncol* 2019; 20(11): 1506-1517.
- Vivaldi C et al.**, Immune Checkpoint Inhibitors in Esophageal Cancers: are we Finally Finding the Right Path in the Mist? *Int J Mol Sci* 2020; 21(5).
- Klein O et al.**, Immunotherapy of Ipiilimumab and Nivolumab in Patients with Advanced Neuroendocrine Tumors: A Subgroup Analysis of the CA209-538 Clinical Trial for Rare Cancers. *Clin Cancer Res* 2020; 26(17): 4454-4459.
- Chau I et al.**, Nivolumab (NIVO) plus ipilimumab (IPI) or NIVO plus chemotherapy (chemo) versus chemo as first-line (1L) treatment for advanced esophageal squamous cell carcinoma (ESCC): First results of the CheckMate 648 study. *J Clin Oncol* 2021; 39(suppl 15): abstr LBA4001).
- Zhang T et al.**, The binding of an anti-PD-1 antibody to FcγRI has a profound impact on its biological functions. *Cancer Immunol Immunother* 2018; 67(7): 1079-1090.
- Shen L et al.**, Tislelizumab in Chinese patients with advanced solid tumors: an open-label, non-comparative, phase 1/2 study. *J Immunother Cancer* 2020; 8(1): e000437.
- Shen L et al.**, RATIONALE 302: Randomized, phase 3 study of tislelizumab versus chemotherapy as second-line treatment for advanced unresectable/metastatic esophageal squamous cell carcinoma. *J Clin Oncol* 2021; 39(suppl 15): abstr 4012).
- Xu R et al.**, ESCORT-1st: A randomized, double-blind, placebo-controlled, phase 3 trial of camrelizumab plus chemotherapy versus chemotherapy in patients with untreated advanced or metastatic esophageal squamous cell carcinoma (ESCC). *J Clin Oncol* 2021; 39(suppl 15): abstr 4000).
- Huang J et al.**, Camrelizumab versus investigator's choice of chemotherapy as second-line therapy for advanced or metastatic oesophageal squamous cell carcinoma (ESCCORT): a multicentre, randomised, open-label, phase 3 study. *Lancet Oncol* 2020; 21(6): 832-842.
- Fuchs CS et al.**, Ramucirumab with cisplatin and fluoropyrimidine as first-line therapy in patients with metastatic gastric or junctional adenocarcinoma (RAINFALL): a double-blind, randomised, placebo-controlled, phase 3 trial. *Lancet Oncol* 2019; 20(3): 420-435.
- Moehler M** Nivolumab (nivo) plus chemotherapy (chemo) versus chemo as first-line (1L) treatment for advanced gastric cancer/gastroesophageal junction cancer (GC/GEJC)/esophageal adenocarcinoma (EAC): First results of the CheckMate 649 study. *Ann Oncol* 2020; 31 (suppl 4): S1142-S1215.
- Moehler M et al.**, First-line (1L) nivolumab (NIVO) plus chemotherapy (chemo) versus chemo in advanced gastric cancer/gastroesophageal junction cancer/esophageal adenocarcinoma (GC/GEJC/EAC): Expanded efficacy and safety data from CheckMate 649. *J Clin Oncol* 2021; 39(suppl 15): abstr 4002).
- van Hagen P et al.**, Preoperative chemoradiotherapy for esophageal or junctional cancer. *N Engl J Med* 2012; 366(22): 2074-84.
- Kelly RJ et al.**, Adjuvant Nivolumab in Resected Esophageal or Gastroesophageal Junction Cancer. *N Engl J Med* 2021; 384(13): 1191-1203.
- Kato K et al.**, KEYNOTE-590: Phase III study of first-line chemotherapy with or without pembrolizumab for advanced esophageal cancer. *Future Oncol* 2019; 15(10): 1057-1066.
- Shah M et al.**, Multicenter, randomized phase II study of neoadjuvant pembrolizumab plus chemotherapy and chemoradiotherapy in esophageal adenocarcinoma (EAC). *J Clin Oncol* 2021; 39(suppl 15): abstr 4005).
- Xu J et al.**, Efficacy and safety of KN046 plus paclitaxel/cisplatin as first-line treatment for unresectable locally advanced, recurrent or metastatic esophageal squamous cell carcinoma (ESCC). *J Clin Oncol* 2021; 39(suppl 15): abstr 4062).
- Harjupää H et al.**, TIGIT as an emerging immune checkpoint. *Clin Exp Immunol* 2020; 200(2): 108-119.
- Frentzas S et al.**, ADVANTIG-105: Phase 1 dose-escalation study of anti-TIGIT monoclonal antibody ociperlimab (BGB-A1217) in combination with tislelizumab in patients with advanced solid tumors. *AACR* 2021, Poster 2583.
- Rodriguez-Abreu D et al.**, Primary analysis of a randomized, double-blind, phase II study of the anti-TIGIT antibody tiragolumab (tira) plus atezolizumab (atezo) versus placebo plus atezo as first-line (1L) treatment in patients with PD-L1-selected NSCLC (CITYSCAPE). *J Clin Oncol* 2020; 38(suppl 15).
- Xu, R et al.**, AdvanTIG-203: A randomized phase 2 study comparing anti-TIGIT ociperlimab plus tislelizumab versus tislelizumab plus placebo as second-line treatment in patients with advanced or recurrent esophageal squamous cell carcinoma (ESCC) expressing programmed death-ligand 1 (PD-L1). *J Clin Oncol* 2021; 39 (suppl 15): abstr TPS4150).
- Al-Batran, SE et al.**, Perioperative chemotherapy with fluorouracil plus leucovorin, oxaliplatin, and docetaxel versus fluorouracil or capecitabine plus cisplatin and epirubicin for locally advanced, resectable gastric or gastro-oesophageal junction adenocarcinoma (FLOT4): a randomised, phase 2/3 trial. *Lancet* 2019; 393(10184): 1948-1957.
- Tokunaga, M et al.**, Perioperative chemotherapy for locally advanced gastric cancer in Japan: current and future perspectives. *Surg Today* 2020; 50(1): 30-37.
- Sexton, RE et al.**, Gastric cancer: a comprehensive review of current and future treatment strategies. *Cancer Metastasis Rev* 2020; 39(4): 1179-1203.
- Yu, WD et al.**, Mechanisms and therapeutic potentials of cancer immunotherapy in combination with radiotherapy and/or chemotherapy. *Cancer Lett* 2019; 452: 66-70.
- Janjigian, Y et al.**, MATTERHORN: Efficacy and safety of neoadjuvant-adjuvant durvalumab and FLOT chemotherapy in resectable gastric and gastroesophageal junction cancer—A randomized, double-blind, placebo-controlled, phase 3 study. *J Clin Oncol* 2021; 39(suppl 15): abstr TPS4151).
- Janjigian Y et al.**, Pembrolizumab plus trastuzumab and chemotherapy for HER2+ metastatic gastric or gastroesophageal junction (G/GEJ) cancer: Initial findings of the global phase 3 KEYNOTE-811 study. *J Clin Oncol* 2021; 39(suppl 15): abstr 4013).

ASCO Congresses

www.memo
inoncology.com

Expert interviews at ASCO 2021



Peter R. Galle overviews the role of immunotherapy in the setting of hepatocellular carcinoma as well as biomarker-based patient selection and discusses which novel combinations of immune checkpoint inhibitors with other drug classes are most promising at present and how those novel strategies impact the treatment landscape.



Roberto Pazo-Cid outlines recent insights gained in terms of anti-PD-1 treatment in the setting of esophageal squamous cell carcinoma, talks about the practice-changing results obtained in the CheckMate 649 trial and the impact of PD-1 inhibition on the real-world prognosis of patients with gastric and esophageal adenocarcinoma as well as further developments regarding immune checkpoint inhibition.

For **more expert interviews** and educational materials around lung cancer please visit our memo InOncology webpage


(www.memoinoncology.com)

Here you will find the latest memo inOncology issues reporting on ASCO, ELCC and ESMO 2019 and previous years in English, Japanese and Mandarin!

Read memo inOncology **congress reports** of ASCO, EHA and ESMO 2020 and watch video interviews with Key Opinion Leaders!

Learn about the new memo inOncology - **medical educational series**, which provides information from preceptorships to clinical trials trainings.

Sign up for the memo inOncology **Newsletter** on memoinoncology.com to keep yourself updated on all exciting news and developments in lung cancer.



Forthcoming Special Issue

This special issue will be offering a synopsis from the ESMO 2021 that will be held in September 2021. The report promises to make for stimulating reading, as the ESMO Congress itself draws on the input from a number of partner organizations, representing a multidisciplinary approach to cancer treatment and care. Again, solid tumors will be at the heart of this special issue.



ESMO 2021 Annual Meeting

16-21 SEPTEMBER 2021

